

Improving Our Patients Quality of Life:

# Creation of the Bruxzir Hybrid to Increase Form and Function



by Timothy Kosinski, DDS, MAGD

**E**dentulous patients are presenting to our practices requesting specific information on the widely publicized permanent restorations that will restore their form and function. These appliances are referred to as “hybrids” or bridges that have gingival colored material needed for lip support and to make the tooth design normal looking. Many people are no longer satisfied with a diminished quality of life with their often uncomfortable or ill-fitting conventional removable dentures. Part of our responsibility as dental professionals is to keep current with the newest innovations and procedures available. Implant dentistry has become a routine and predictable

means of restoring edentulous spaces. Engineering our cases well helps provide for a long-term solution to a significant dental problem.

These implant retained hybrid appliances are extremely esthetic, increase chewing efficiency, provide a palateless design, and exhibit excellent wear characteristics. They are also very strong and resistant to chipping or fracturing. The zirconia materials now available can be precisely milled as one solid piece.

Diagnosis is the most critical part in deciding the possibility of creating such a dental device to individual patients. Vital anatomy is reviewed

including the position of the maxillary sinuses and mandibular nerves.<sup>1</sup> The lingual concavity can be evaluated. Proper design of the final prosthesis is determined by the implant number and strategic placement. Understanding arch form is critical to the final stability of the prosthesis and how many posterior teeth can be created. Misch stated that we can predictably cantilever 1.5 times the distance from a line drawn between the two most anterior contralateral implants and the most posterior implants in the arch.<sup>2</sup>

More recent advances in CAD/CAM design and materials has allowed us to eliminate the use of titanium supported acrylic based/denture tooth hybrids and often replace them with milled monolithic zirconia.<sup>3</sup> CBCT soft ware evaluation advancements have also created an ability to visualize the case prior to any final digital processing. Form and function are all determined using our computer design.

These full arch prostheses are attached to the implants through either custom milled abutments, which allows the prosthesis to be cemented into place or through titanium copings which allow screws to retain the prosthesis in the mouth. This material allows for fracture and wear resistance and is considered the highest advancement in dental construction today. It must be noted that not every edentulous case can be restored using this high- tech procedure. The monolithic zirconia (Bruxzir, Glidewell

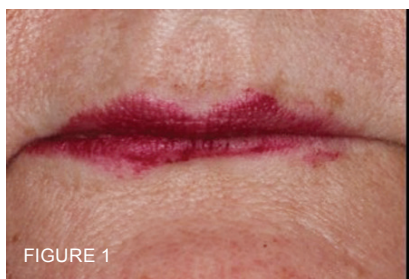

FIGURE 1

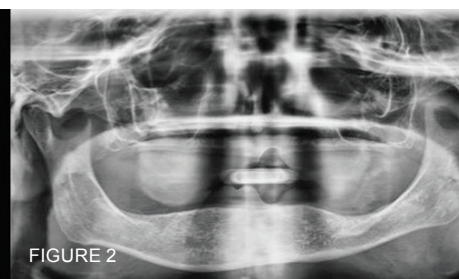


FIGURE 2

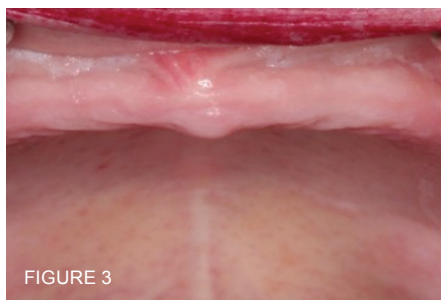

FIGURE 3

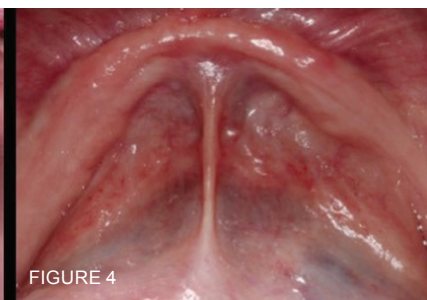

FIGURE 4

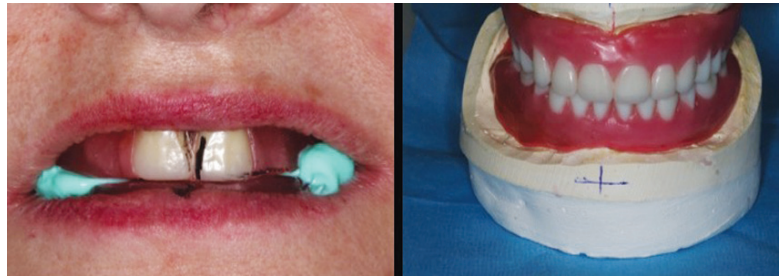
**Figure 1, 2, 3 & 4:** Pre-operative smile and panoramic radiograph of our edentulous patient and her maxillary and mandibular edentulous ridges.

Laboratories, Newport Beach, CA) is created in a round form, ala a hockey puck design. The interarch distance, the amount of bone loss and the width of the patient's edentulous arch determine whether the entire hybrid prosthesis, including the gingival area and tooth areas, can be milled using the single zirconia puck.<sup>4</sup> Thus it is imperative that the dentist work with their laboratory to determine proper design prior to promising the patient the final result. However, when it is possible, the Bruxzir solid zirconia has wonderful esthetic characteristics. The zirconia is also wear compatible with the enamel of opposing teeth.<sup>5</sup>

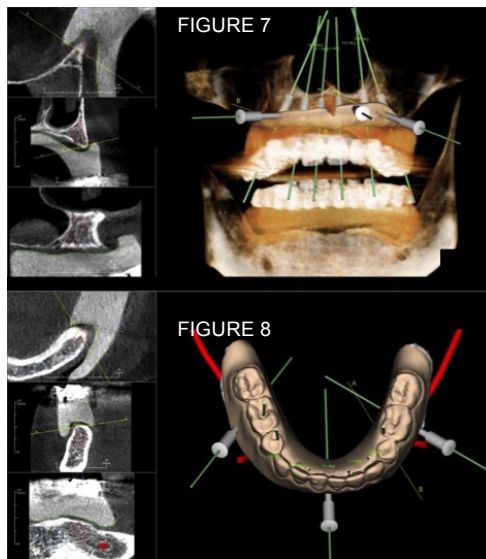
Proper Implant placement is imperative. So often a cone beam CT is used to determine proper position (Vatech America, Green CT, NJ). It is imperative that a proper fitting denture appliance be made where the intaglio surface

These implant retained hybrid appliances are **extremely esthetic**, increase **chewing efficiency**, provide a **palateless design**, and exhibit **excellent wear** characteristics.

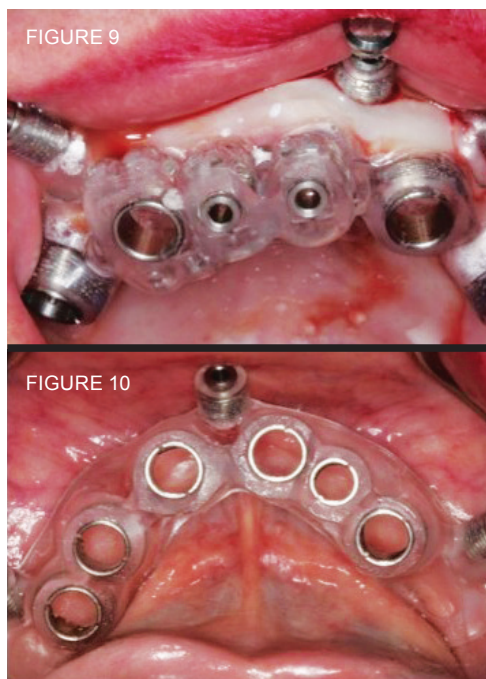
rests firmly on the tissue. This denture is scanned separately out of the mouth with some type of radiopaque markers and again with the patient wearing them as the CT is taken. Following digital design of implant placement and approximation of tooth position, a CT surgical guide can then be fabricated. When creating a digital design of implant placement (Anatomage, San Jose, CA) we can determine the precise final tooth position, which will determine whether a solid zirconia bridge can be fabricated using the round puck shaped material, or whether conventional bar and acrylic hybrids are fabricated. The diagnosis also helps determine where screws will extend out of the appliance. Sometimes screws come out in inappropriate places and a fixed prosthesis using custom milled abutments is preferred.



**Figures 5 & 6:** Prior to CBCT diagnosis, a proper fitting conventional maxillary complete denture is fabricated with the intaglio surface of the denture completely seated on the soft tissue of the ridge. Any discrepancy here could result in an ill fitting surgical guide and surgical complications.



**FIGURES 7 & 8:** Using dental implant software (Invivo 5, Anatomage) the implants are virtually precisely positioned to maximize the use of available hard tissue.



**FIGURES 9 & 10:** Surgical guides are created to allow for osteotomy preparation in the positions within the arch to maximize stability and function.

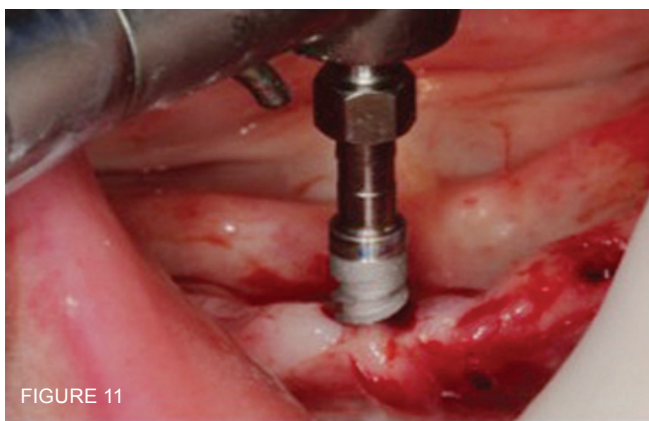


FIGURE 11

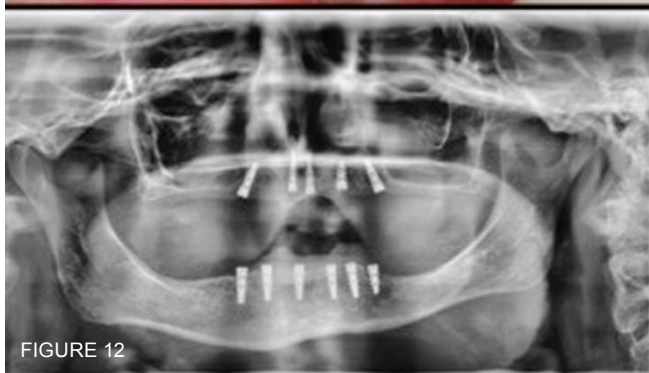

FIGURE 12

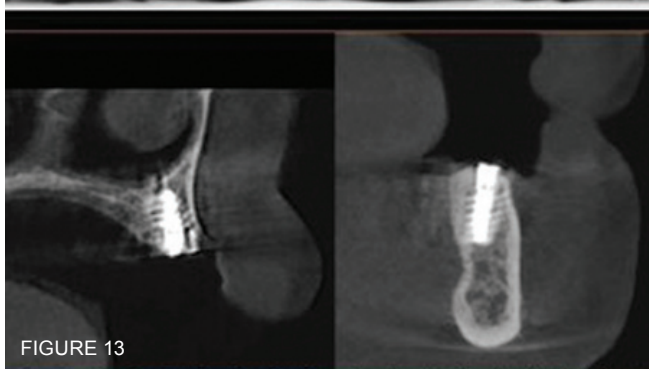

FIGURE 13

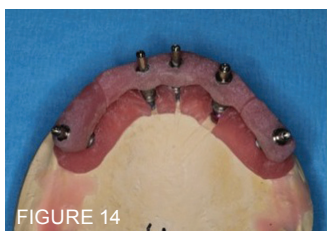


FIGURE 14

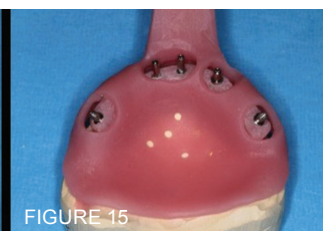

FIGURE 15

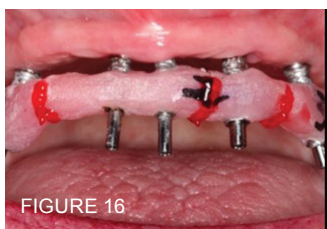


FIGURE 16

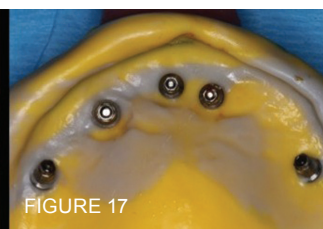

FIGURE 17

Osteotomies for the Hahn dental implants (Glidewell Lab) are completed through the surgical guides and the implants threaded to place. Once the implants have integrated, a clean impression is made using polyvinylsiloxane materials (Kettenbach, Huntington Beach, CA) and a stone cast fabricated. A conventional wax set up using denture teeth help the technician and dentist establish horizontal and vertical positioning to the patient's expectations. These are tried in to establish proper esthetics and lip support. Because the process is precise, prior to the final milling the dental laboratory will fabricate positioning jigs which are threaded into the mouth intraorally, and luted together with composite or duralay type products. A custom open tray impression picks up these jigs and provides the dental laboratory with an extremely accurate final impression and master cast.

A provisional smilecomposer appliance is fabricated and seated in the patient. Occlusion and esthetics are again evaluated and the patient can even leave with this provisional in place to insure that they are satisfied with the results. Once determined that the fit and function is accurate, the final Bruxzir monolithic zirconia hybrid appliance is CAD/CAM created and milled and seated into the arch.

In my opinion, this Bruxzir monolithic solid zirconia hybrid prosthesis is the most esthetic and natural appliance we can create today.

### Conclusion:

As we discuss options for our edentulous patients, it is important to realize the advantages and disadvantages of each prosthesis we create. Conventional dentures may be proper for some people, but may be a detriment to others. Removable implant retained overdentures certainly improve chewing function and eliminate the palate from a maxillary denture and can be a God send to many patients. Those patients that request fixed prostheses, also have options. If many implants are placed, custom abutments and bridgework can be created. Hybrid appliances offer another solution which also may be cost effective to the

**FIGURES 11, 12 & 13:** Hahn dental implants (Glidewell Lab) are torqued to final placement and verified with a conventional panoramic radiograph and post operative CBCT analysis.

**FIGURES 14, 15, 16 & 17:** Following initial impressions using conventional transfer assemblies, the dental lab creates the preliminary cast. From this verification jigs are fabricated and seated onto the individual implants. These pieces are luted together and a final pick up impression is made with polyvinylsiloxane material (Kettenbach medium and heavy body) in a custom tray. The open tray concept insures a more precise final impression used to fabricate the master casts.

public. Conventional acrylic based, denture tooth hybrids work well but will wear over time. The newest CAD/CAM designed Bruxzir solid zirconia hybrids are the most durable and esthetic appliances I fabricate. We must know the anatomic limitations to each option as well as material and instrumentation limitations. Understanding each prosthetic option will help our patients improve chewing function and create beautiful esthetics which psychologically can improve their overall quality of life.

*Dr. Timothy Kosinski is an Affiliated Adjunct Clinical Professor at the University of Detroit Mercy School of Dentistry and serves on the editorial review board of Reality, the information source for esthetic dentistry, the Michigan Dental Association Journal, and is the past editor of the Michigan Academy of General Dentistry and currently Associate Editor of the AGD journals. He is a Past-President of the Michigan Academy of General Dentistry. Dr. Kosinski received his DDS from the University of Detroit Mercy Dental School and his Mastership in Biochemistry from Wayne State University School of Medicine. He is a Diplomat of the American Board of Oral Implantology/Implant Dentistry, the International Congress of Oral Implantologists and the American Society of Osseointegration. He is a Fellow of the American Academy of Implant Dentistry and received his Mastership in the Academy of General Dentistry. Dr. Kosinski has received many honors including Fellowship in the American and International Colleges of Dentists and the Academy of Dentistry International. In 2017 he received the Academy of Dentistry International's Humanitarian Award "in recognition of significant contributions to the enhancement of the quality of life and the human condition." He is a member of OKU and the Pierre Fauchard Academy. Dr. Kosinski was the University of Detroit Mercy School of Dentistry Alumni Association's "Alumnus of the Year," and in 2009 and 2014 received the Academy of General Dentistry's "Lifelong Learning and Service Recognition." Dr. Kosinski has placed over 13,000 dental implants and published over 190 articles on the surgical and prosthetic phases of implant dentistry.*

**References**

1. Wu YQ, Huang W, Zhang ZY, et al. Tilted implants treatment without maxillary sinus grafting in severely resorbed posterior maxilla [in Chinese]. Shanghai Kou Qiang Yi Xue. 2011;20:506-511
2. Misch, CE. Contemporary Implant Dentistry. 3rd 3d. St. Louis, MO: Mosby Elsevier; 2008:293-310, 383-386.
3. Christensen, GJ. Bruxzir and e.maxCAD: Superior clinical performance at 3+ years. Clinicians Report. June 2014. 7(6): 1-3.
4. Carames, J, Tovar S et al. Clinical Advantages and Limitations of Monolithic Zirconia Restorations: Full arch implant supported reconstruction. Int. J Dent. 2015: 392-396.
5. Tischler M. A maxillary fixed bridge supported by dental implants: treatment sequence and soft-tissue considerations. Compend Contin Educ Dent. 2012;33:340-344.




FIGURE 18

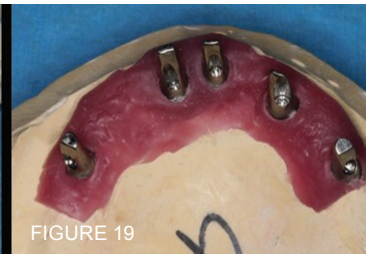

FIGURE 19

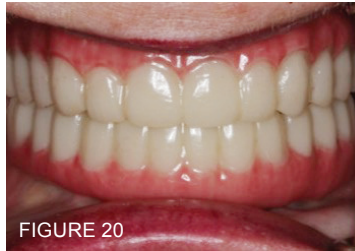

FIGURE 20

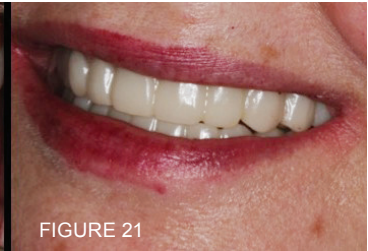

FIGURE 21

**FIGURES 18, 19, 20 & 21:** Because of the available bone and pre-determined positioning of the implants, it was decided to fabricate custom titanium abutments. This design eliminates screw access holes protruding through the facial aspect of the prostheses. Smile composers are transitional appliances made of a PMMA material. The patient is able to evaluate form and function prior to milling of the final Bruxzir hybrid appliances. This step eliminates extensive adjustments in the final product.

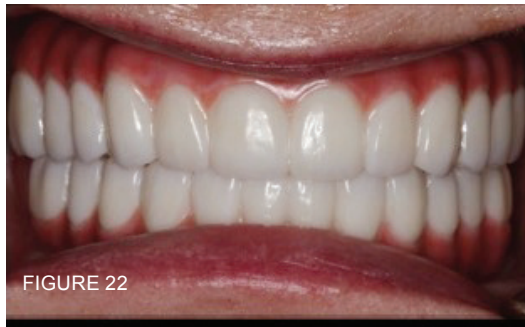

FIGURE 22




FIGURE 23

**FIGURES 22, 23 & 24:** Final radiograph of completed restorations and final esthetic and functional result. The pre operative photo was provided to me as a guide for what our patient expected esthetically.

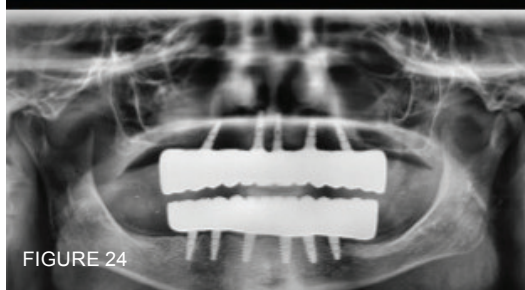


FIGURE 24