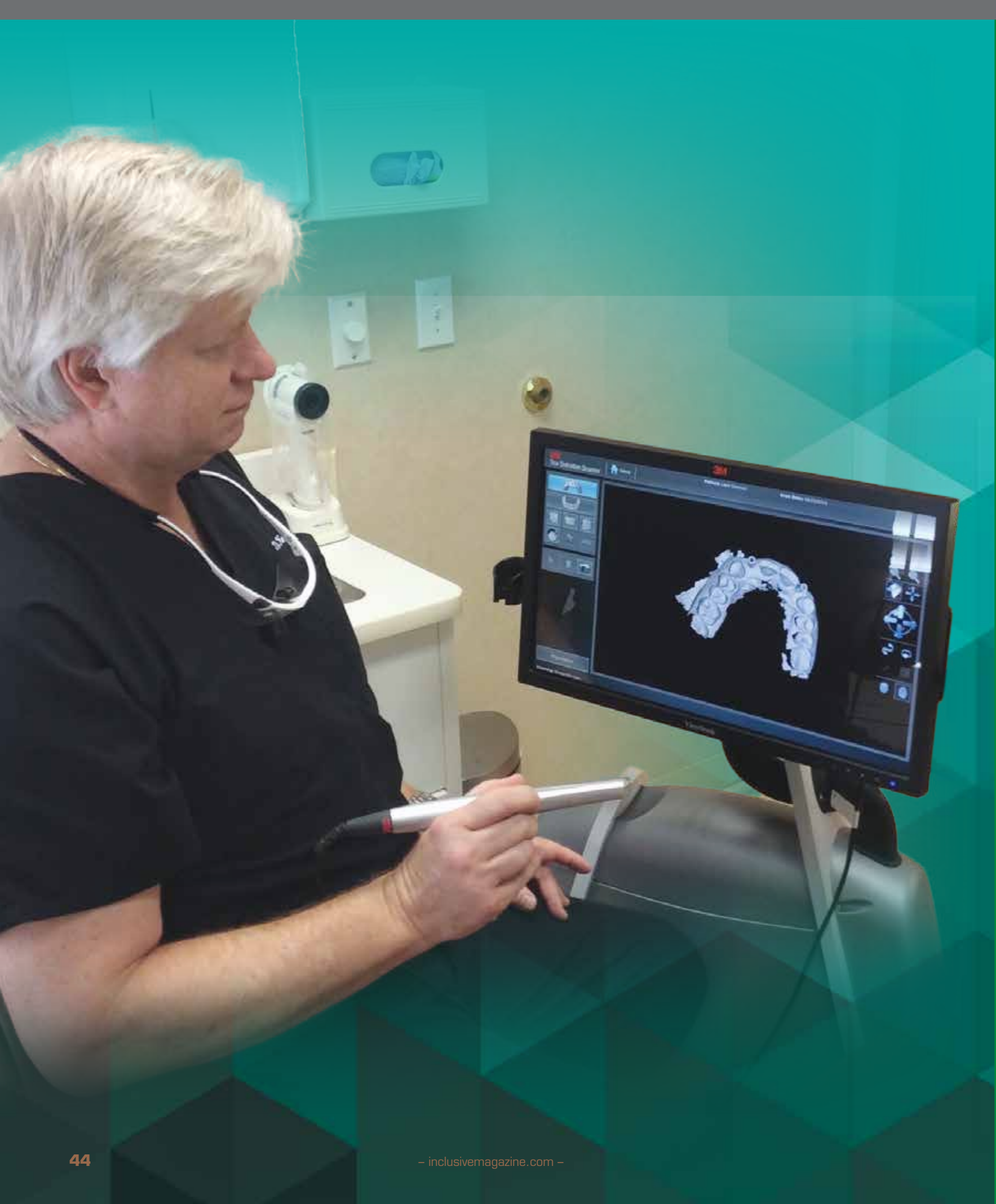
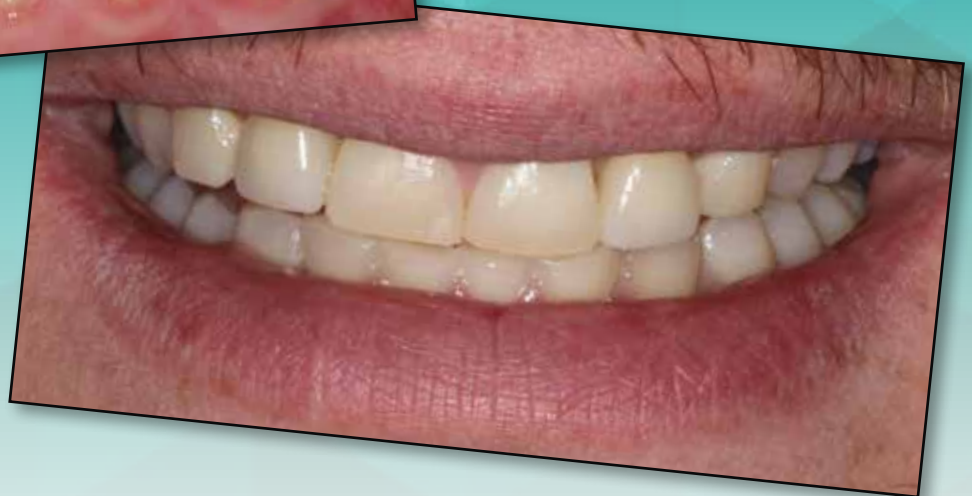
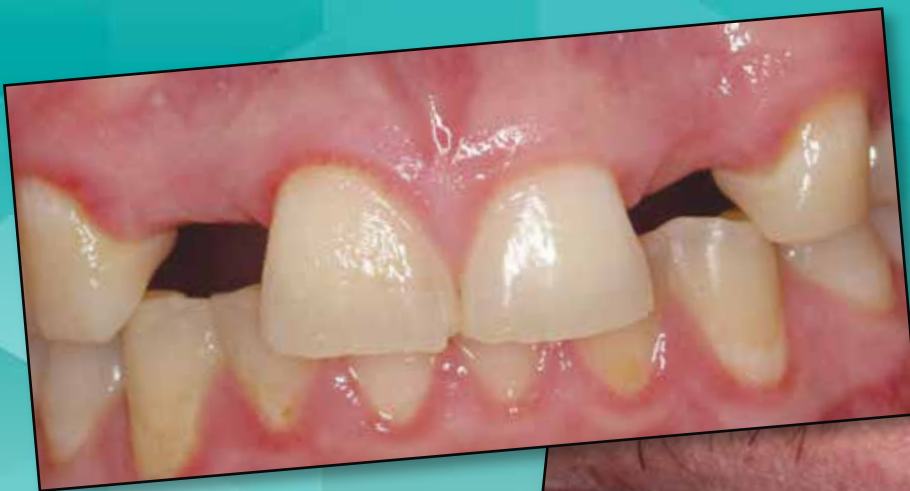

# Resolving Functional and Esthetic Concerns in the Maxillary Anterior Region



*by* **Timothy F. Kosinski, DDS, MAGD**

When one or more teeth are missing, there can be both functional and psychological effects on the patient. Implant dentistry has become a viable alternative to conventional dental procedures and should certainly be discussed with patients as a solution to their concerns. Here, we'll discuss how proper implant selection and placement can work hand in hand with the implementation of zirconia hybrid abutments and solid zirconia crowns, resulting in an esthetic and functional solution for restoring edentulous spaces in the smile zone.

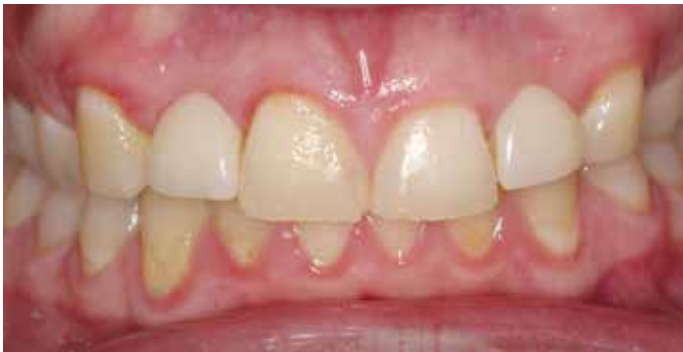## CASE ANALYSIS

The lateral incisor edentulous space can be one of the more difficult sites in which to surgically place dental implants. First, the maxillary bone contours can make ideal positioning of the implant challenging. Second, the facial plate of bone may be thin. A minimum of 1 mm of facial and palatal plate of bone is required to establish immediate stability, allow for an esthetic emergence profile, and eliminate the possibility of grey from the implant showing through the soft tissue.

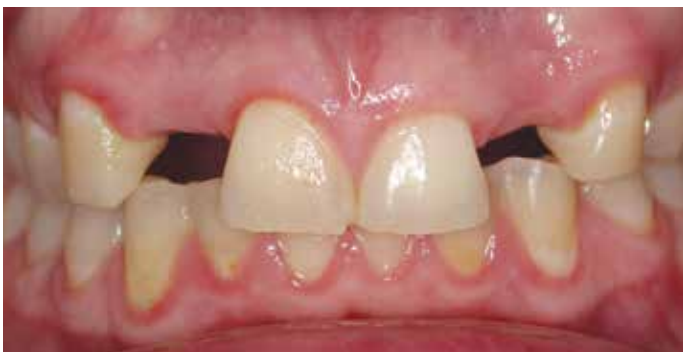The patient, a 25-year-old male with no medical complications, presented with congenitally missing maxillary right and left lateral incisors, replaced with a removable partial denture that he found unsatisfactory (Figs. 1, 2). The Hahn™ Tapered Implant System, with its pronounced thread design and ability to accommodate tight anatomical spaces, was selected to restore the edentulous sites, as minimal horizontal bone was present.

## IMPLANT PLACEMENT

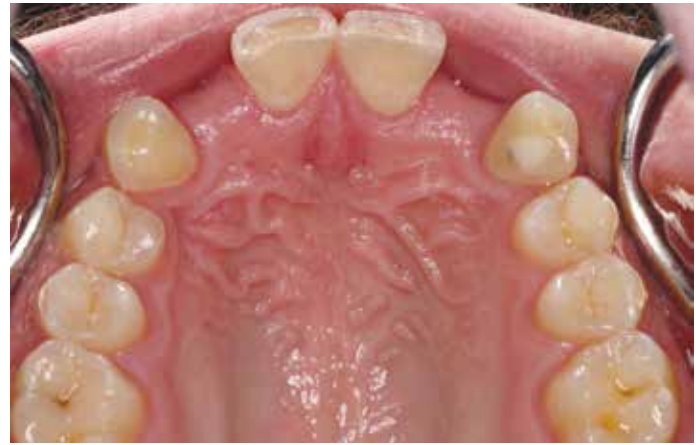When placing dental implants, the dentist must be certain that the angulation, depth and position of the implants are appropriate to allow for a natural emergence profile, which requires a comprehensive evaluation of the patient's bone volume and anatomy (Figs. 3, 4). Several techniques are available to achieve this goal. Here, a scan was made using the PaX-i3D Green Imaging System (Vatech America, Inc.; Fort Lee, N.J.). The sagittal view of the scan illustrates the amount of available bone (Fig. 5). The amount and quality of bone was precisely determined with the imaging software. Virtual placement of the implants can also be performed, helping the doctor choose the proper implant size and visualize how the implant should be positioned in the edentulous space.



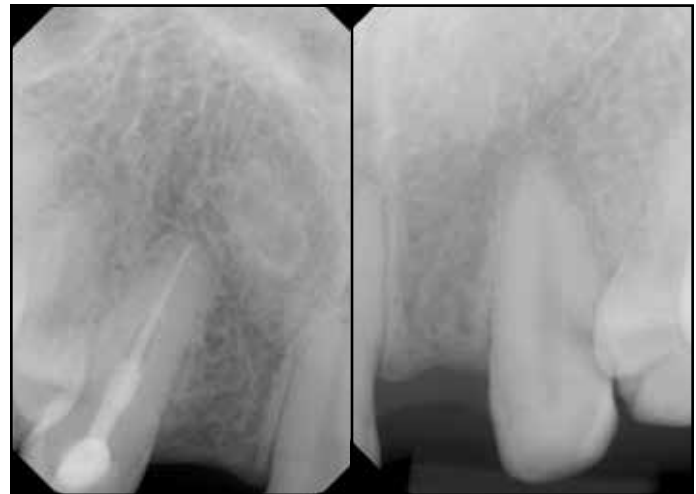
**Figure 1:** The patient presented wearing a removable flipper appliance, which had been provided as a replacement for his missing maxillary right and left lateral incisors.



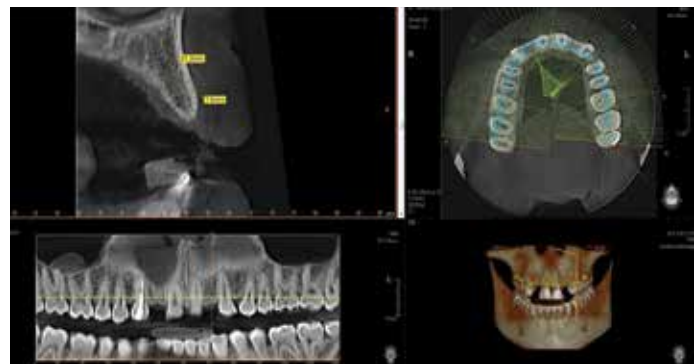**Figure 2:** Because the maxillary lateral incisors had been in place for a long time prior to tooth loss, there was adequate bone volume available for implant placement.



**Figure 3:** Occlusal view of edentulous spaces illustrating adequate mesial-distal and facial-palatal ridge width.



**Figure 4:** Digital periapical radiographs exhibit acceptable vertical bone height. The apices of the adjacent teeth are used as a preliminary guide in determining the appropriate lengths of implants.

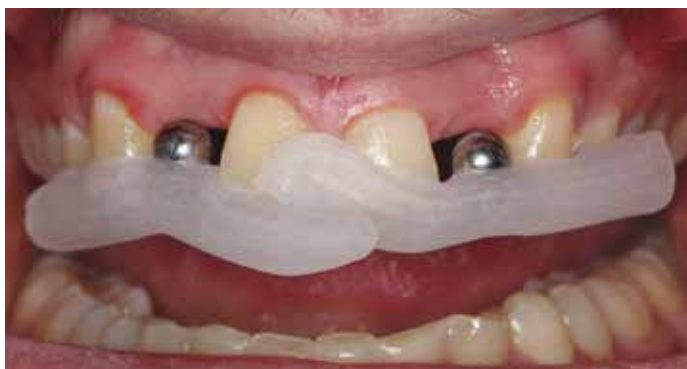

**Figure 5:** CBCT analysis illustrates the available bone height and width to accept dental implants.

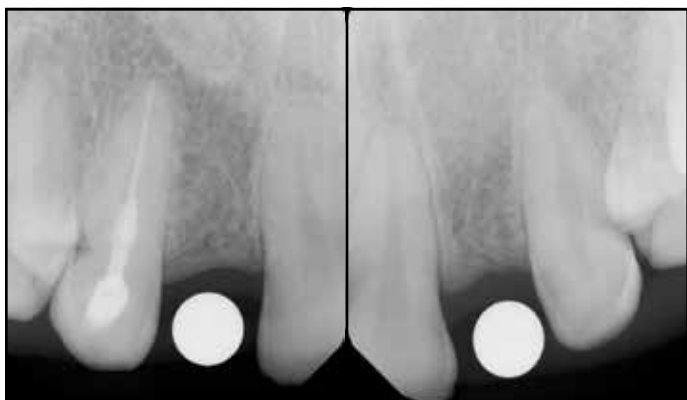
Because the patient's anatomy in the edentulous spaces did not present any complications, the implants were placed without the use of a surgical guide.

The case can also be predictably planned with conventional two-dimensional digital radiographs. Ball bearings of a known diameter, such as 5 mm, can be placed in the patient's mouth and used to calibrate DEXIS imaging software (DEXIS; Alpharetta, Ga.), which can then be utilized to record accurate radiographic measurements (Fig. 6). This allows for precise determination of available vertical bone for dental implants (Fig. 7). Horizontal dimensions can be determined using bone calipers or flapping the site to provide a visualization of the available bone and morphology (Figs. 8, 9).

To create proper emergence profiles for the implant-retained crowns in the maxillary right and left lateral incisor positions, the 2 mm pilot drill was centered between the teeth adjacent to the edentulous sites (Fig. 10). The osteotomies were positioned approximately 3 mm palatal

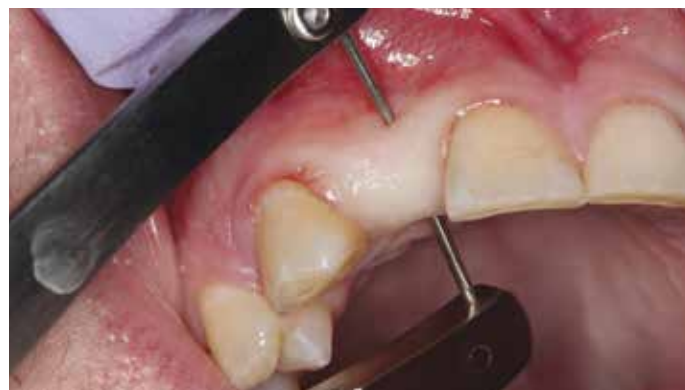

**Figure 6:** The 5 mm ball bearings placed in orthodontic wax are used during digital periapical radiography. This helps accurately determine the amount of available bone.

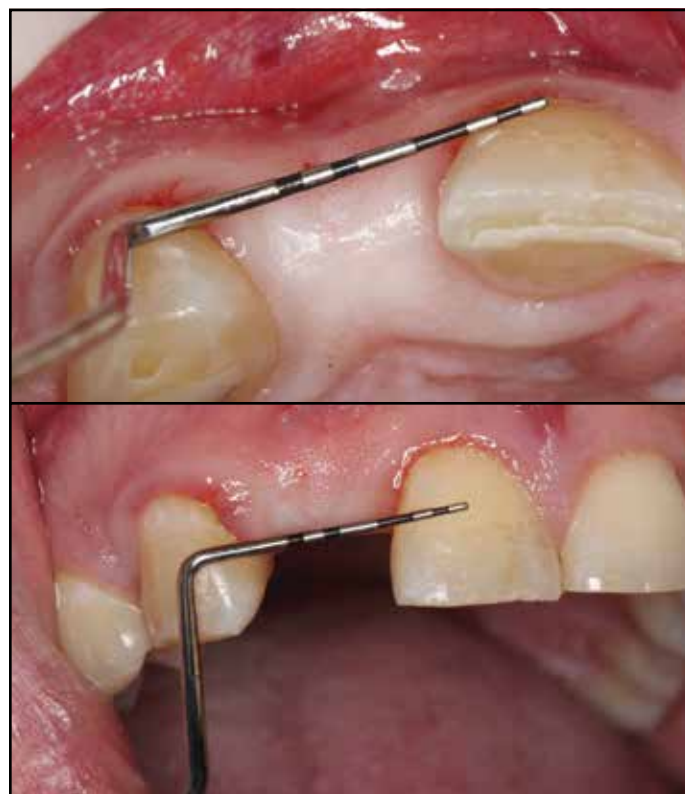

**Figure 7:** A radiograph of the 5-mm-diameter ball bearings in place. Proportional analysis using the DEXIS system software allows for accurate measurement of vertical bone.

*The dentist must be certain that the angulation, depth and position of the implants are appropriate.*



**Figure 8:** A bone caliper can be used following infiltration anesthesia to determine facial-palatal bone width.

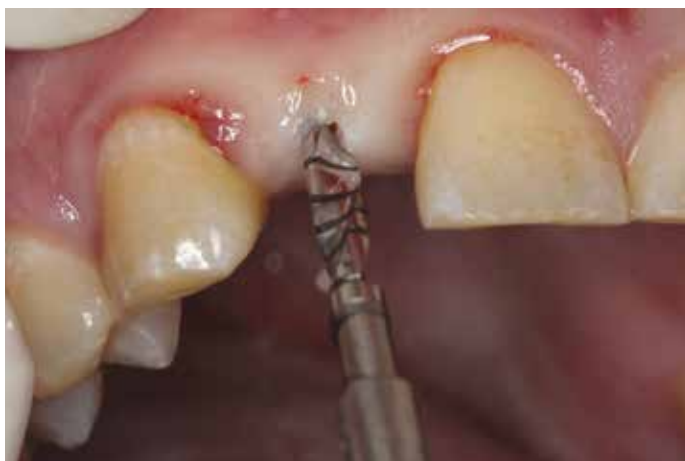

**Figure 9:** Visualization of the eventual emergence profile is determined. The initial osteotomy is made approximately 3 mm palatal to the facial aspect of the adjacent teeth. This allows adequate room for the custom abutment and final crown.

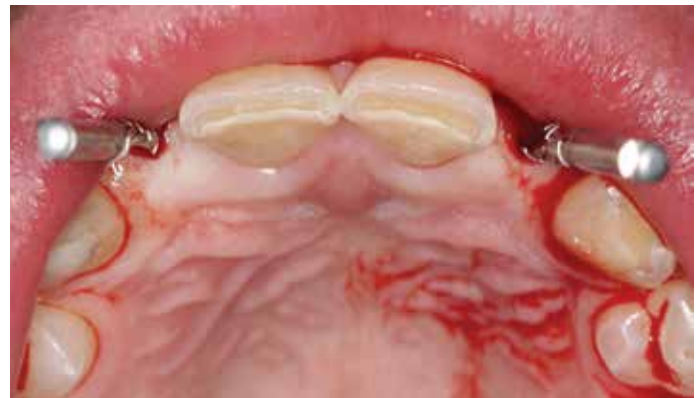to the facial aspect of the adjacent dentition to allow for the best esthetics and enough facial room for a custom abutment and implant-retained crown (Fig. 11). The mesial-distal angulation of the drill was checked with a digital periapical radiograph (Fig. 12). A tissue punch was used to remove the tissue above the osteotomy preparation, ensuring that the epithelium would not penetrate into the socket (Figs. 13, 14).

The Hahn Tapered Implant System surgical kit was used to create osteotomies slightly smaller in diameter than the 3-mm-diameter implants chosen for this case. An implant length of 11.5 mm was used for the maxillary right incisor and 13 mm for the maxillary left incisor. The diameter, length and tapered body of the implants were ideal for the limited space available (Figs. 15, 16). Additionally, the implants feature prominent threads, which ease insertion into the undersized osteotomy site. The ability to place an implant in a slightly smaller osteotomy can help ensure outstanding primary stability (Fig. 17). This is especially important where bone quality is not ideal. Cover screws were hand-tightened into position so that the patient could continue wearing his transitional appliance during the healing period (Figs. 18, 19).

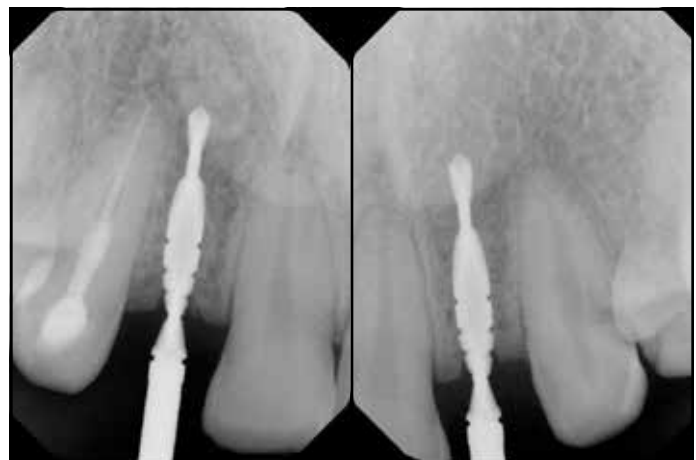*The diameter, length and tapered body of the implants were ideal for the limited space available.*



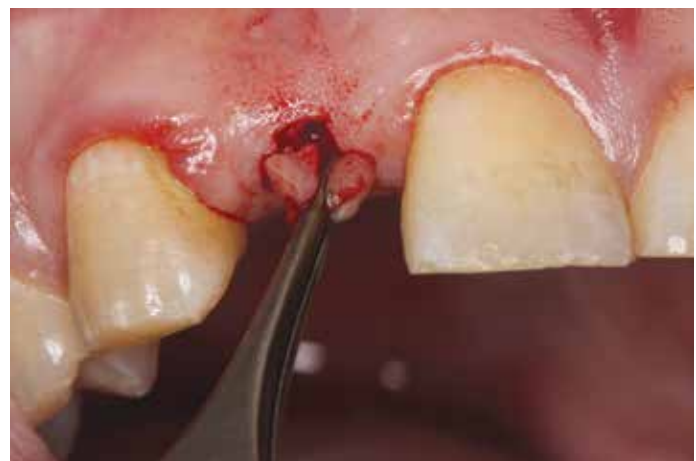**Figure 10:** The Hahn Tapered Implant System pilot drill is used to correctly angulate the implant osteotomy.



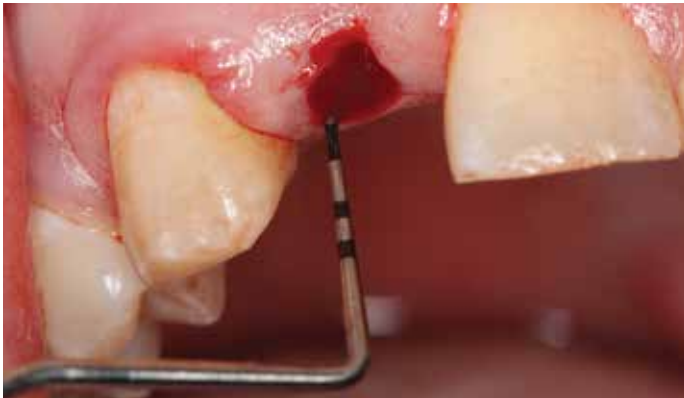**Figure 11:** Occlusal view of initial osteotomies. Note how the contour of the available bone determines proper positioning. The anterior maxillary bone is often thin and angled. Care must be made to position the implant such that there is no facial dehiscence created. If the exact bone contour is unclear, a conventional flap should be made to visualize the available bone.



**Figure 12:** Radiographs help in verifying mesial and distal positioning. Note how the dark spaces mesial and distal to the surgical drill are nearly identical. Depth is also verified using the apices of the adjacent roots as a safety guide. At this point, angulation can be corrected as necessary.



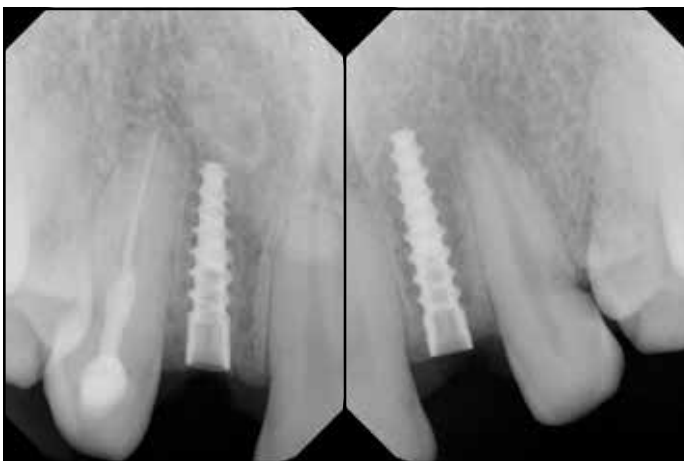**Figure 13:** A tissue punch is used to remove the attached gingiva above the prepared osteotomy site, preventing tissue from engaging the osteotomy hole.



**Figure 14:** Tissue depth can be easily determined following the removal of attached gingiva at the surgical site. This helps with ensuring proper positioning of the implant using a flapless technique.



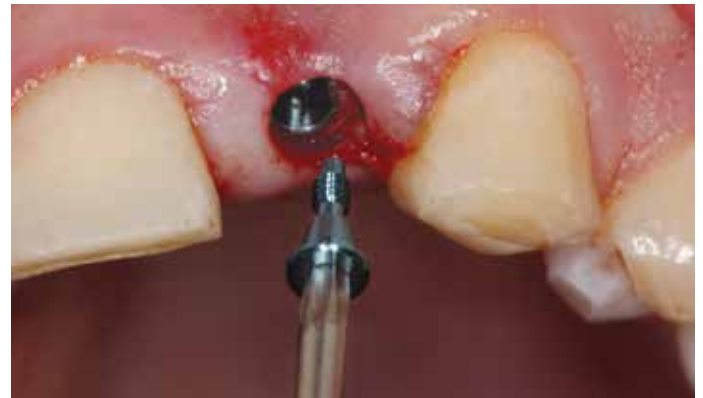**Figure 15:** The Hahn Tapered Implant engages the prepared osteotomy sites and is placed at 25 rpm.



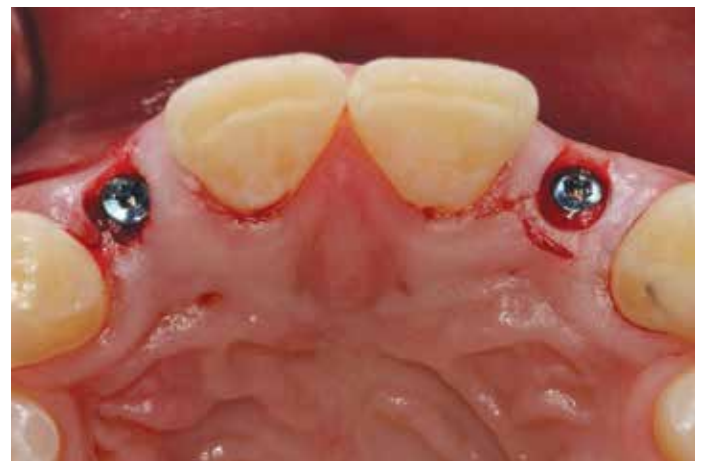**Figure 16:** Periapical radiographs illustrate ideal positioning of the Hahn Tapered Implants.



**Figure 17:** The implants were threaded into position and achieved ideal initial stability.



**Figure 18:** Because the patient wanted to continue wearing his transitional appliance, cover screws were placed and the implants were buried.



**Figure 19:** The cover screws in place. Note the ideal position of the implants.

## DIGITAL WORKFLOW

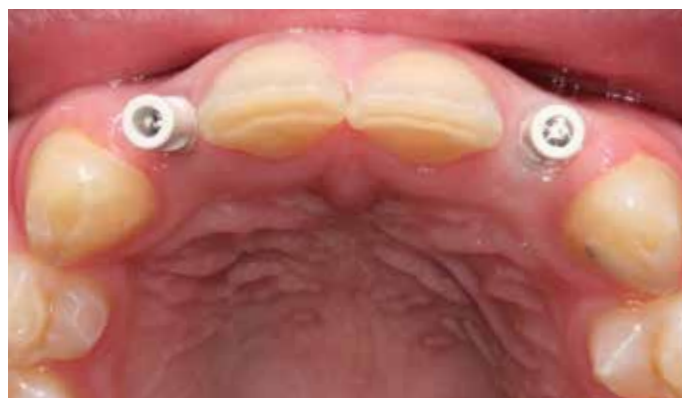After approximately four months, the implants were uncovered, Inclusive® Scanning Abutments (Glidewell Direct; Irvine, Calif.) were threaded into each implant, and a digital impression was made (Fig. 20). The 3M™ True Definition Scanner (3M ESPE; St. Paul, Minn.) is a digital impression system consisting of a computer on a mobile cart and a compact, lightweight wand. The scanning wand is a handheld optical device that captures high-resolution video images, in real time, as the patient is being scanned.

The digital technology captures clear and highly accurate impression data in minutes, without the need for traditional impression materials that some patients find inconvenient and messy (Fig. 21). The creation of highly accurate images allows for fabrication of precise restorations that fit well with minimal adjustment. The 3M True Definition Scanner used here produces open STL files, which means that the scans are easily exported to CAD/CAM systems in place at the dental lab.

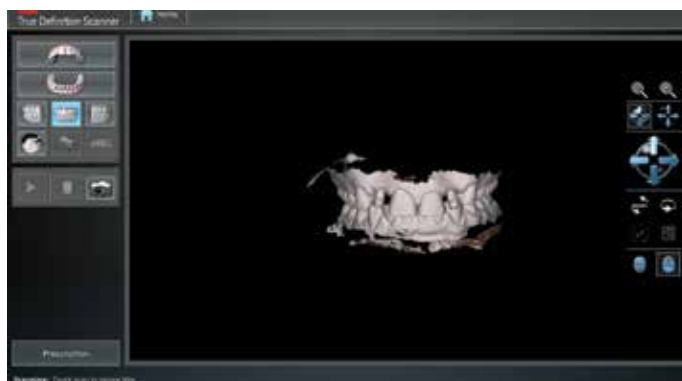
From the digital scan, the lab created custom zirconia hybrid abutments and BruxZir® Anterior crowns to establish an ideal emergence profile (Fig. 22). The BruxZir Anterior crowns were selected for their high esthetic value and durability. The margins of the custom abutments were designed to be equigingival or just slightly subgingival, simplifying cement removal and eliminating the possibility of cement remnants creating periodontal issues (Figs. 23, 24). The BruxZir Anterior crowns were cemented over the custom abutments without difficulty (Fig. 25). The final restorations created excellent function and esthetic emergence profiles (Fig. 26).

## CONCLUSION

When clinicians embrace the technology of digital scanning and CAD/CAM prosthetic design, the resultant efficiency and proficiency make dentistry enjoyable and predictable. Working with a high-quality dental lab that understands the intricacies of dental implant crown and bridge construction provides the opportunity to maximize the results of the restoration. The Hahn Tapered Implant supports an optimal treatment outcome, providing initial stability, bone healing and prosthetic components that allow for an esthetic emergence profile. Indeed, ideal results can be readily achieved using the innovative technology available to us today. **IM**

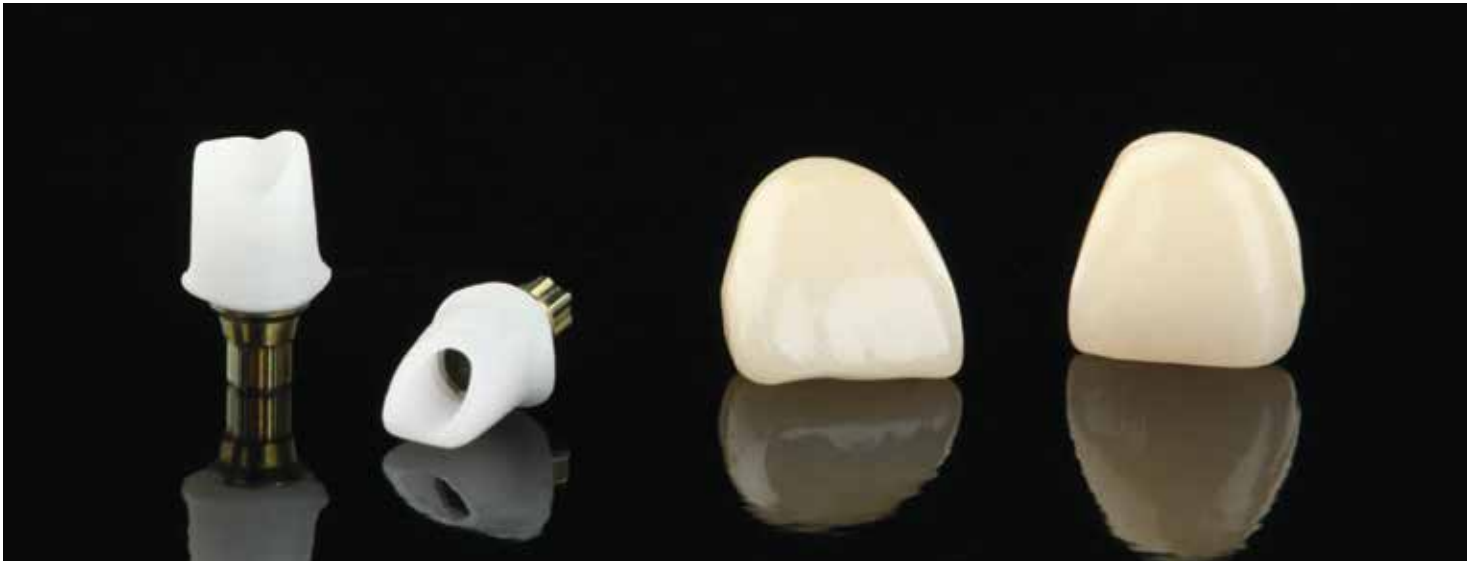

**Figure 20:** Scanning abutments are threaded into each implant.

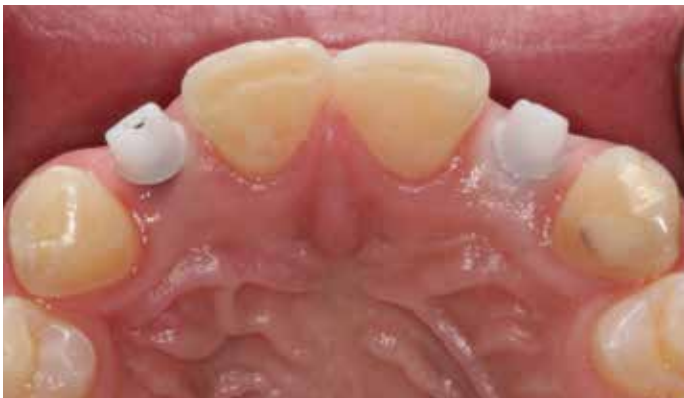

**Figure 21:** The digital impression is generated and submitted electronically to the lab. No impression material is used, making it convenient for the patient and the practitioner.

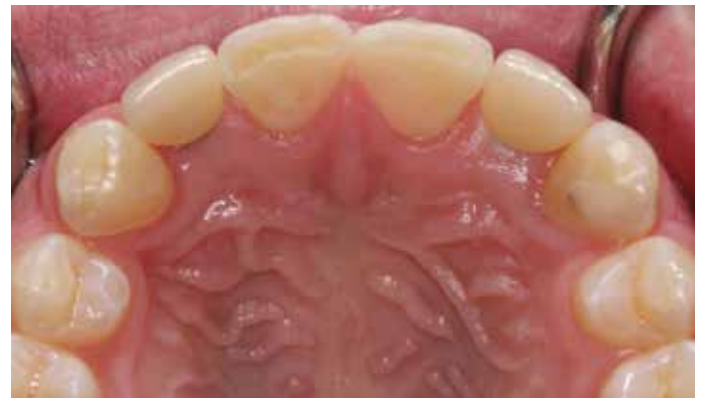*From the digital scan, the lab created custom zirconia hybrid abutments and BruxZir Anterior crowns to establish an ideal emergence profile.*



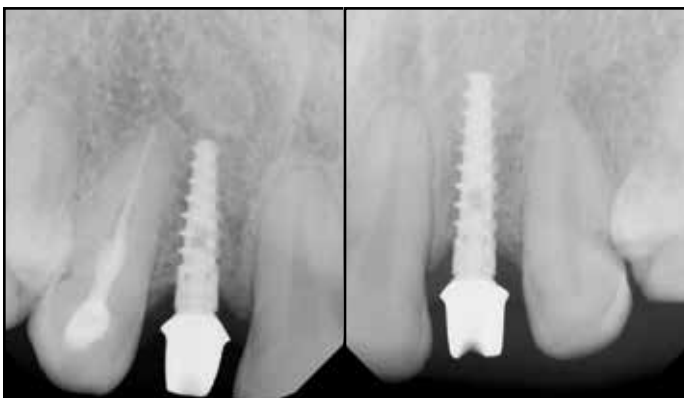**Figure 22:** Inclusive® Custom Zirconia Abutments with titanium bases and BruxZir Anterior crowns were fabricated based on the digital scan, ensuring proper function and an esthetic emergence profile.



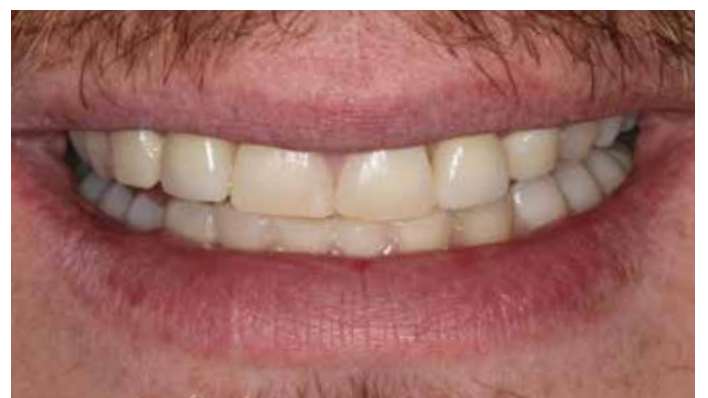**Figure 23:** Occlusal view of custom zirconia hybrid abutments in position. Note that the margins are equigingival or just slightly subgingival, making periodontal maintenance easy and cement cleanup predictable.



**Figure 25:** Esthetic BruxZir Anterior crowns cemented into place.



**Figure 24:** Periapical radiograph of custom abutments in place on the Hahn Tapered Implants.



**Figure 26:** The restorations address both functional and esthetic concerns, which can often be a challenge in the smile zone.