

## Utilizing Digital Treatment Planning and Guided Surgery in Conjunction with Narrow-Body Implants

by Timothy F. Kosinski, DDS, MAGD

Implant dentistry is undergoing some amazing transformations. With the help of CT diagnosis and digital treatment planning, general dentists can predictably surgically place and restore many different designs of dental implants to improve quality of life for their patients. Innovations in design and materials have made our job as clinicians less complicated and more successful. Implant dentistry has entered into the mainstream mindset as well, with many patients asking about the benefits of dental implants. However, we sometimes are presented with challenges relating to bone quality or quantity, anatomic restraints and esthetic complications. The therapeutic goal of implant dentistry is oral rehabilitation and improved form and function. When we include dental implants in our diagnostic armamentarium, we provide patients with hope for a long-term positive result. Modern technology and design enable us to surgically place implants in compromised areas.

The patient in this case, a 64-year-old white female, had been edentulous for more than 25 years. Although her maxillary conventional complete denture was retentive and provided lip support for esthetics, her mandibular conventional complete denture was never completely stable and dramatically diminished her perceived quality of life. Although well made, the mandibular conventional denture provided her with decreased chewing function. As the years progressed, the denture became less tolerable due to the instability of the appliance, and the patient's interest in dental implant reconstruction became more apparent. There were no apparent medical complications for this procedure. Oral and radiographic examination revealed good vertical height of the mandibular ridge.

CT diagnosis allowed us to visualize the patient's available bone in three dimensions and to virtually place the implants prior to any surgical intervention. CT scanning has fast become an important tool in the diagnosis and treatment of dental implant position and placement. Especially in areas of the mouth where bone contours are difficult to determine with conventional radiography and oral palpation alone, CT scanning software allows for determination of bone quantity and quality.<sup>1</sup> For the less experienced clinician, this tool also helps determine potential risks involved in surgical placement. Correct position in bone and angulation are determined prior to any surgical intervention. CT planning software also helps eliminate potential manual placement errors and can match the surgical planning to the eventual prosthetic reconstruction. Finally, the software allows for surgery to be less invasive and more predictable because there is no longer a need for full-thickness flap procedures. Instead, the implants are placed using a flapless approach, which is less uncomfortable for the patient and allows for improved post-operative healing.

When considering dental implant placement in the mandibular arch, compromised conditions can result in poor positioning or angulation, which will make fabrication of the final prosthesis difficult. The main objective in dental implant placement is improving stability of the denture and providing retention, thus increasing chewing efficiency. Over time, the implants will minimize further bone loss.

A patient's understanding of the benefits of dental implant therapy is certainly a motivator to patient acceptance. Wearing a removable appliance can be difficult to tolerate physically and emotionally. Creating an appliance with improved retention and stability helps alleviate functional and psychological concerns.

The 3.0 mm I-Mini® IOT/O-ball dental implant (OCO Biomedical; Albuquerque, N.M.) is proving to be an outstanding small-diameter implant for immediate overdenture stabilization. It is a one-piece implant designed with a ball that serves as the male component to the long-used O-ring system. The design is intended for immediate-load and immediate-function capability. The mini cortical thread pattern at the top of the implant locks into the cortical bone, and a bull-nose "auger" design at the apex condenses bone around the tip and the threads. Dual stabilization locks the implant in place, providing a true mechanical lock. The minimally invasive system offers an outstanding choice in areas of narrow bone. An advantage of this system is that a transitional prosthesis can be immediately placed. In this case, the patient's existing mandibular complete denture was relieved and relined to immediately stabilize her prosthesis.<sup>2</sup>

The surgical technique used to place the OCO Biomedical 3.0 mm I-Mini IOT/O-ball implants was simple and precise. Chairtime was reduced dramatically following diagnosis using CT scanning software and virtual placement of the dental implants using Blue Sky Plan® treatment planning software (Blue Sky Bio; Grayslake, Ill.).

The technology behind digital treatment planning and guided surgery is based on long-used planning algorithms. CT scans and 3-D software improves predictability and safety for the clinician, especially in areas of anatomic concern, such as a thin mandible, as demonstrated in this case. The surgery is driven by the demands of the final esthetic and functional prosthetics. Final tooth position is established prior to any surgical intervention to ensure compatibility between the surgical placement and the clinician's and the patient's expectations of the final result.

CT planning and placement systems provide an increased level of comfort and safety for patients by reducing surgical and restorative chairtime. This is accomplished by utilizing an accurate three-dimensional plan prior to surgical placement of the implants.<sup>3</sup> There are several advantages to doing this. The case is more easily presented to the patient. There is reduced surgical chairtime and reduced prosthetic chairtime because the implants are properly positioned. And in compromised situations, there is reduced stress to the clinician because accurate surgical placement is predetermined, which results in fewer clinical surprises that could cause the clinician to abort the case.

Prior to the CT scan, the dental lab fabricated a scan appliance, which aids in visualizing the optimal prosthetic outcome. The teeth are then properly positioned in wax, or the patient's existing denture can be duplicated if it is well fitting. Either way, a hard appliance is processed to illustrate what the case will look like when finished, before it is even started.

In this particular case, the patient's existing conventional complete denture was duplicated. All appropriate dental anatomy was included. The scan appliance was placed into the mouth during the CT scan.<sup>4</sup> Doing this enables the clinician to see the ideal position of the teeth in a 3-D model. The entire 3-D image is analyzed, and the implant planning and simulation of implant placement completed using the computer. The surgical placement of the implants can be done in a conventional manner using the newly created surgical guide to help direct the drills in the ideal direction. Often this can become a flapless procedure. The implants are then simply placed in the desired depth and direction using the computer software and the surgical guide.<sup>5</sup>

In this case, a surgical guide based on the virtual plan and fabricated by Glidewell Laboratories was utilized. It consisted of 1.8 mm sleeves, which allowed for directional determination of the dental implants to be placed. This surgical guide was fabricated using the information created by the CT scanning software. The guide was used to determine correct directional placement of the implants in the patient's symphysis area. Because bone and soft tissue were compensated for in the fabrication of the surgical guide, no reflection or flap was needed in the placement of the implants.

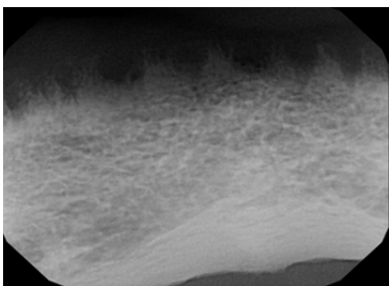


Figure 1: Pre-operative radiograph of the edentulous ridge

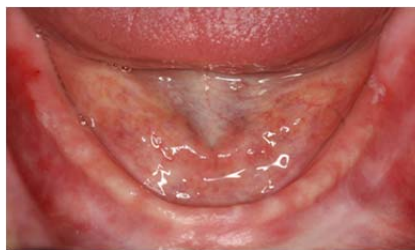

Figure 2: Occlusal view of the thin mandibular ridge

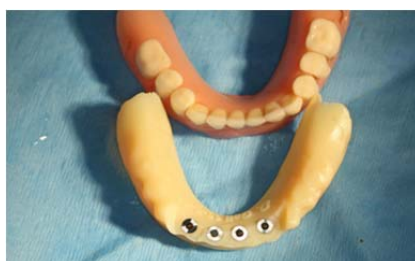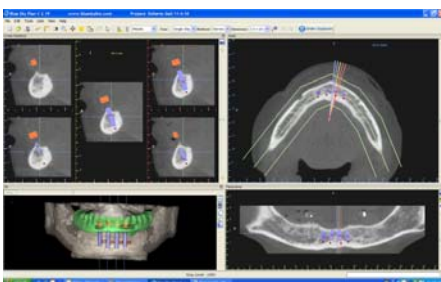


Figure 3: CT scan with virtually placed implants

Figure 4: Surgical guide based on the virtual plan

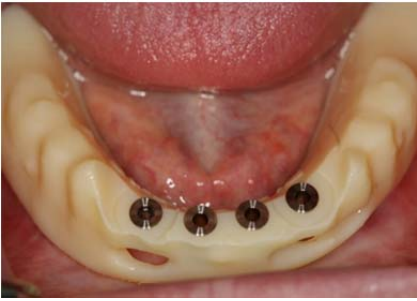

Figure 5: Surgical guide in situ

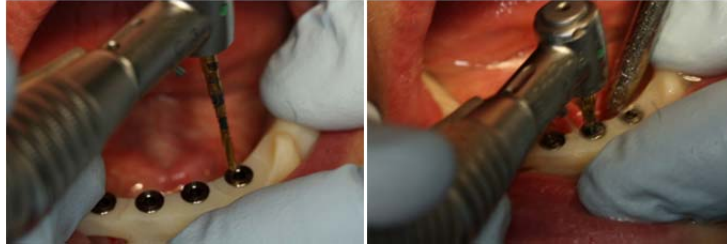

Figure 6: Small-diameter drill going through sleeve of surgical guide

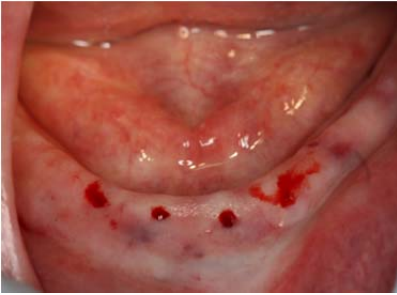

Figure 7: Preparation through soft tissue in a flapless procedure

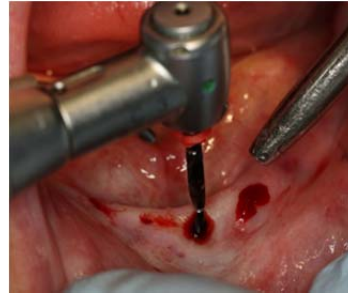


Figure 8: A 1.8 mm pilot drill is used to depth.

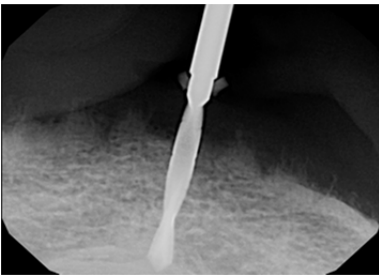


Figure 9: Digital radiograph of pilot drill at proper angulation and depth

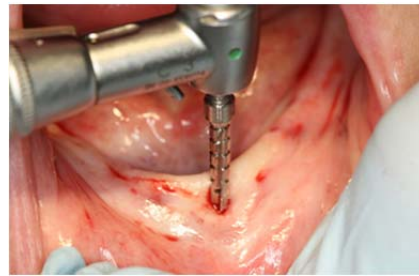


Figure 10: Final 2.4 mm drill for 3.0 mm implant

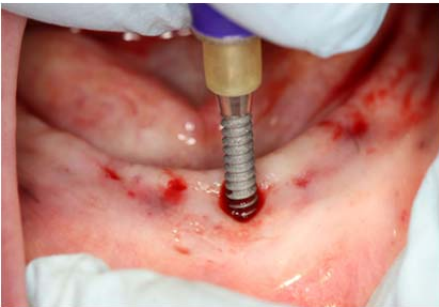

Figure 11: The implant is hand-tightened into the osteotomy site.

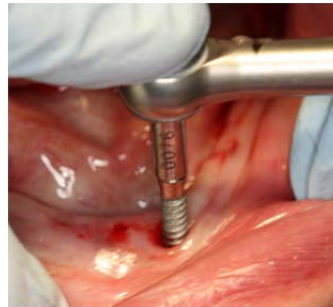


Figure 12: A ratchet is used to position the implant into the bone.

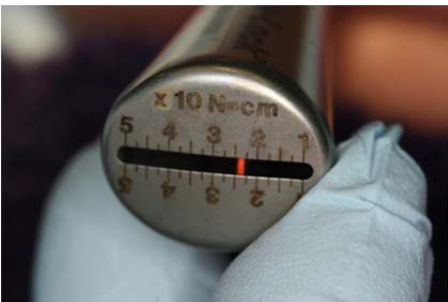


Figure 13: The implant is torqued to over 50 Ncm, indicating excellent primary stability.

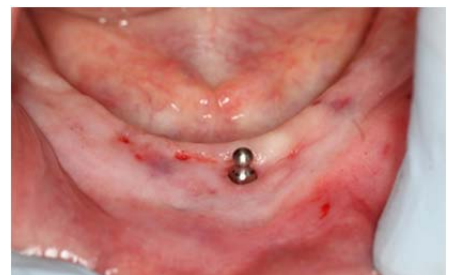

Figure 14: The first mini implant is placed.

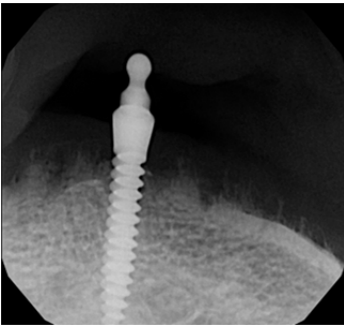


Figure 15: Digital radiograph of the first implant in position

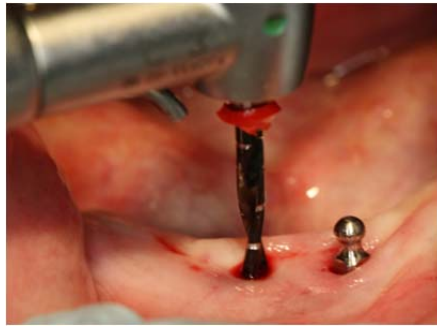

Figure 16: Preparation of the subsequent implant sites

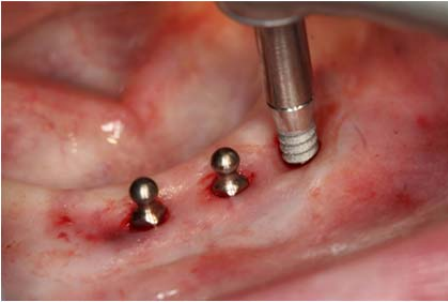


Figure 17: Placement of the remaining implants

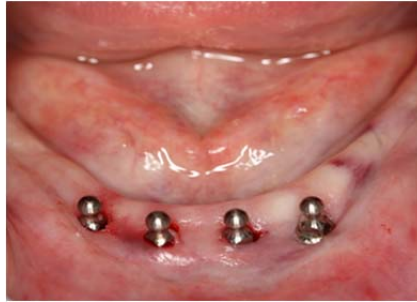

Figure 18: Four small-diameter implants ideally placed in the symphysis area

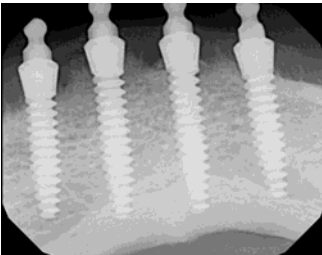


Figure 19: Post-operative radiograph of implants in position

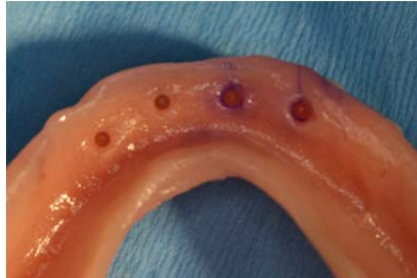
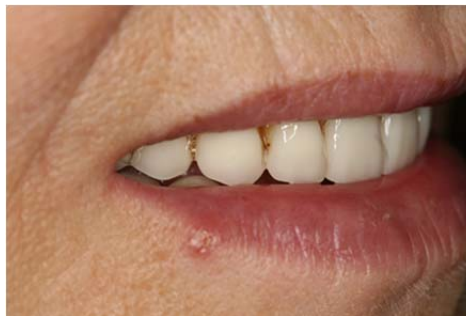
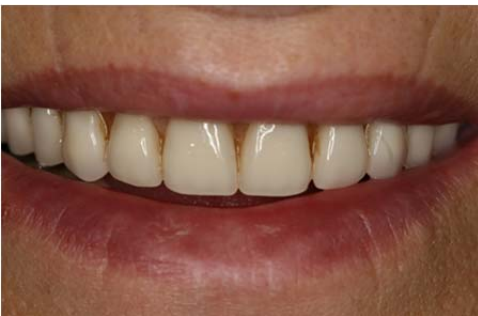Figure 20: Soft relines of patient's existing denture over the implant heads



Figures 21a, 21b: Existing dentures in place. New denture will be fabricated with O-ring retention housings following osseointegration.

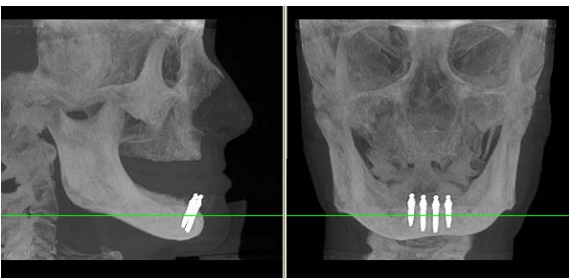


Figure 22a: Post-operative CT scan compared to pre-operative plan

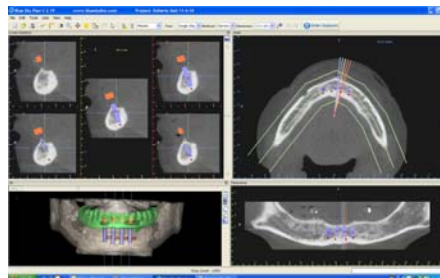


Figure 22b: Digital plan based on the CBCT scan

Although placing mini implants is marketed as a simple procedure, the clinician must understand the patient's anatomy, including the quantity and quality of the bone, as well as the location of the inferior alveolar nerve. This can be accomplished by reflecting a soft-tissue flap. Or, if you select a flapless approach, as in this case, a CBCT scan can be taken and the implants planned in a virtual environment.

Figure 1 shows the preoperative bone morphology in a two-dimensional radiograph. Clinically, there appears to be a thin mandibular ridge (*Fig. 2*). However, the 3-D view reveals a relatively short, wide ridge with a thick cortical plate (*Fig. 3*). Utilizing the patient's existing denture as a scan appliance, we were able to plan the case from a surgical and a prosthetic perspective. Four 3.0 mm implants were planned in the symphysis. The implants were angled slightly to the labial to maximize the length, thus establishing bicortical stabilization and locating the O-ball head of the implants under the anterior teeth of the denture.

The surgical guide with directional sleeves for the pilot drill was fabricated based on the CT scan of the patient's existing, well-fitting conventional complete denture (*Figs. 4, 5*). A small-diameter pilot drill was used through the sleeves of the surgical guide to create proper angulation and position of the four small-diameter implants (*Fig. 6*). Perforations were made through the soft tissue and ridge crest, allowing for directional placement of the implants (*Fig. 7*). The directional guide was then removed and a 1.8 mm drill used to depth as determined by analysis of the CT planning software (*Fig. 8*). The directional openings were used to correctly angle the drills to the predetermined depths — 14 mm for the #23 and #25 implants, and 12 mm for the #22 and #27 implants. A radiograph was taken to ensure proper depth (*Fig. 9*). A 2.4 mm drill was then used to the pre-determined depth to create the osteotomy site for the 3.0 mm mini implant (*Fig. 10*). Because we were using a self-tapping implant, there was no need to use a thread former. The final drill used to form the osteotomy was side-cutting only. The pilot drill alone determined the depth of the implant placement. There were no intermediate-sized drills used in this technique.

The implant was then hand-tightened to establish initial stability, and a torque ratchet was used to thread the implant to the desired depth (*Figs. 11, 12*). Compensation of soft tissue can be determined by using the CT scan, or it can be established by measuring the soft-tissue depth with a periodontal probe following anesthesia. In this case, the initial implant was inserted with a torque of over 50 Ncm (*Fig. 13*), which indicates outstanding primary stability of the implant. It is absolutely critical that the implant be stable after placement. There must be no mobility. As the implant bottoms out, the bone is condensed at the apex by the threads and at the crest by the mini-thread at the bottom of the tapered collar. Once the implant was placed, an additional few turns were given to condense the bone at the tip and wedge the cortical thread into the cortical bone, creating a mechanical lock at the top and bottom of the implant.

Figures 14 and 15 show the first implant in position intraorally as well as radiographically. Subsequent implants were placed using the same protocol (*Figs. 16, 17*). Figures 18 and 19 show the four implants ideally placed in the mandibular symphysis and the final radiograph. Note there is little bleeding, as this was a flapless procedure. Also note that the lingual plate is more coronally positioned than the labial plate, and the implants are positioned in the center of the ridge.

Next, the patient's existing mandibular complete denture was relieved and a chairside soft reline material was placed to stabilize the denture (*Fig. 20*). The patient experienced immediate improvement of the retention and stability of her mandibular denture (*Fig. 21*). She also experienced minimal discomfort following placement of the conditioning material. After integration progresses, a new mandibular implant-retained overdenture with O-rings will be used to create retention, stability and an increased quality of life for our patient. Figures 22a and 22b show the post-operative CT scan as compared to the virtual plan.

The OCO Biomedical 3.0 mm I-Mini one-piece overdenture implant system allowed us to strategically place predictable implants to improve the patient's functional ability. This was a difficult case because the patient had lost significant horizontal and vertical bone. As cost is a factor, especially in today's economy, the small-diameter implant was an excellent option for this patient to improve stability and retention of her mandibular denture. The use of CT diagnosis improved my confidence in proper placement of the dental implants using a flapless procedure, which is much less invasive than cutting a long, full-thickness flap. The patient experienced little to no discomfort following the procedure and appreciated the immediate improvement in the fit of her mandibular denture.

This case demonstrates just one of the innovative techniques available to clinicians and our patients. CT scans and digital planning software make the surgical placement of dental implants simple and effective. Anatomical anomalies are virtually determined prior to any surgical intervention. Using this system, implants can be ideally placed and maintenance is routine.

#### REFERENCES:

1. Williams PA, ed. Overdenture construction of implants directionally placed using CT scanning techniques. *Dental Implantation and Technology*. Nova Science Publishers. 2010;197–208.
2. Fortin T, Champleboux G, Bianchi S, Buatois H, Coudert, JL. Precision of transfer of pre-operative planning for oral implants based on cone-beam CT-scan images through a robotic drilling machine: an in vitro study. *Clinical Oral Implants Res*. 2002;13:651-56.
3. Fortin T, Bosson JL, Isidori M, Blanchet E. Effect of flapless surgery on pain experienced in implant placement using an image-guided system. *Int J Oral Maxillofac Implants*. 2006;21(2):298–304.
4. Kosinski T, Kline R. Case presentation: overdenture alternative with narrow-body implants. *Implant News and Views*. 2006;8(5):1.
5. Kosinski T. CT planning for implants: don't let a panoramic fool you. *Inclusive*. 2010;1(4):43–50.