

# Innovative Socket Grafting Techniques in Preparation for Dental Implants



by Timothy Kosinski, DDS, MAGD

Socket preservation is often referred to as simple. However, there is still some confusion among dentists in determining the type of graft material that should be used in these preservation techniques. It is assumed that when a tooth is lost to extraction, bone changes will occur with the residual socket site shrinking. The bone will often resorb apically and facially, leaving a shorter, thinner remaining ridge. Ideal dental implant placement relies on adequate bone to place the fixture. The maxillary posterior region creates some unique compromises when considering a dental implant.(1)

First the maxillary molar has three distinct roots, mesial facial, distal-facial and palatal. The palatal root is often the longest and widest root. Immediate placement of a modern dental implant in this site is difficult. Placing the implant immediately in the mesial or distal positioned root will create an implant retained crown that is facially contoured resulting in esthetic and functional complications. The palatal root would be a nice site to surgically place an implant. However, using this palatal socket would result in an implant retained crown that is too far on the palate, resulting in speech defects and angst to the tongue.

Ideally implants should be positioned along the central groove areas of the adjacent teeth. To achieve this better dental implant position requires socket preservation techniques to help maintain

available bone. The other major issue with implant placement in the maxillary molar site is that when the tooth is surgically removed, the sinus floor will collapse, similar to what happens to a circus tent when the tent poles are removed. The tent simply falls.

Too often our patients present with missing maxillary first molar areas, which are still in the esthetic zone of their smiles. The available height and width of bone is often compromised to the level that a proper dental implant cannot be considered without significant invasive surgical procedures to either at best tent the sinus floor or at worst require a sinus augmentation. Both these procedures increase the eventual cost to the patient.

So my question here is, is it better for the patient to provide a simple socket preservation with minimal initial expense or a more expensive future invasive surgical procedure to build bone back up after it is lost? When explained well to our patients, most would prefer to preserve bone in the least traumatic way possible.

Dental implants require adequate bone quality and quantity to establish initial stability and eventual osseointegration. The two socket preservation techniques described here create new bone over time in a challenging site of the maxillary first molar. Both techniques provide me an adequate foundation. Several types of grafts are available to us today. Autogenous grafts, or material taken from the patient's own body, has long

been considered the "gold standard."

The growth factors from the autogenous material allow for predictable bone replacement. Autogenous grafts are typically harvested from another site on the patient's body, normally the ramus or the symphysis area. This requires a second surgical site where the bone is harvested from with some potential for increased discomfort.

Allograft materials are very popular today. These materials are harvested from the same species. Cortical and cancellous bone is ground to a powder and processed for safety from disease transmission. The allografts have proven to be an excellent alternative to autogenous grafts because a second surgical site of the harvested bone is not required. Bone turnover takes a little longer.

A third type of graft material is referred to as alloplastic, or synthetic. There are several materials on the market today including hydroxyapatite, tri-calcium phosphate, ceramics and polymers.(2) These products have grown and fallen out of favor over the years for many reasons. The fourth type of graft material used in dentistry is xenografts, or material harvested from another species.(3)

We are demonstrating two innovative methods of grafting an extraction socket that provide predictable results in preparation for dental implants that are different from your conventional allograft procedures. First I will demonstrate a

very simple graft procedure that is easy to implement, as well as very affordable in terms of product cost, as the procedure does not require the use of a membrane. Secondly I will demonstrate a procedure that allows me to use the dentin from extracted teeth to create autogenous graft material in a practical and safe manner.

My hope here is to demonstrate unique protocols to help provide some alternatives to conventional grafting products and techniques.

Conventional collagen plugs are often promoted as simple socket preservation material. However, my experience is that most collagen is resorbed in a very short time (7-10 days) and although good for hemostasis, they are not necessarily proper to maintain height and width of bone. OsteoGen Plugs (Impladent, Jamaica, NY) are a homogenous mixture of graft and collagen yielding an easy and efficient product designed for socket preservation. The graft component is OsteoGen, a bioactive, non-ceramic calcium phosphate based bone graft that is similar to human bone mineral and helps to control migration of connective tissue (FIGURES 5-7) The OsteoGen crystals and crystal clusters have been used for over 30 years and has shown documented clinical success for use with implants in periodontal procedures (8,9), general osseous repair (10) and sinus lifts (FIGURES 11-14)

Although radiolucent at the time of placement, we can have a truly objective image as natural bone is formed, and the site becomes more radiopaque. The collagen component is type 1 collagen derived from bovine Achilles tendon and helps to promote keratinized soft tissue coverage. (FIGURES 15-16)

During the method of creating an autogenous bone graft without the need for a second surgical site, I will extract a

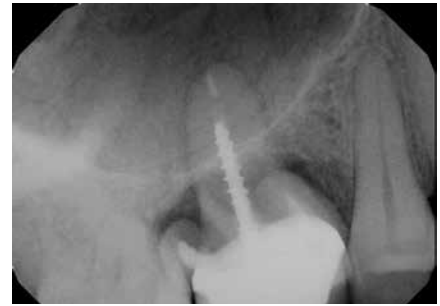
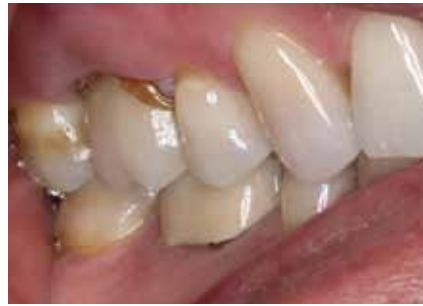
FIGURE 1 & 2: Pre-op photo and digital radiograph of the non-restorable maxillary right first molar with significant bone loss.

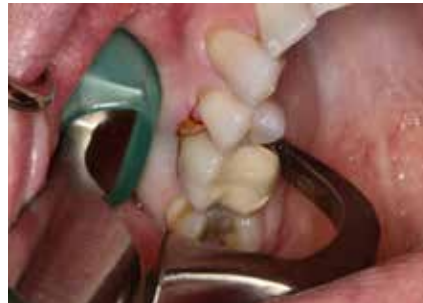

FIGURE 3: The Physics forceps (GoldenDent, Detroit, MI) are used to atraumatically extract the tooth in an efficient manner while maintaining the facial plate of bone.

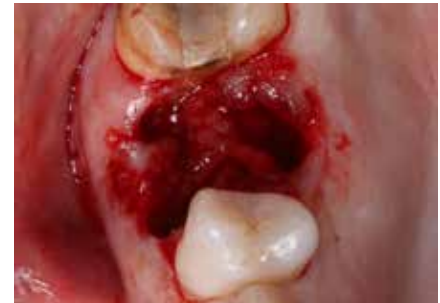

FIGURE 4: Post extraction site. The granulation tissue is carefully curetted out of the socket.

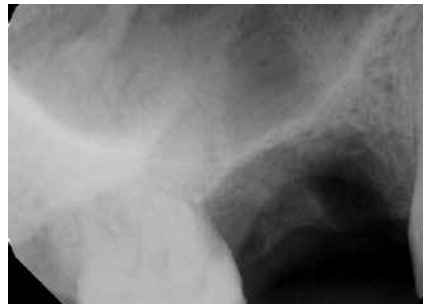

FIGURE 5: Post operative radiograph of extracted site, while maintaining the facial plate of bone.

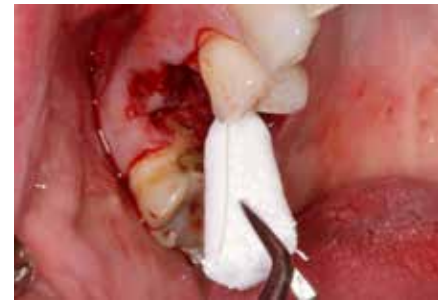

FIGURE 6: An OsteoGen Plug will conform to the shape of the socket.

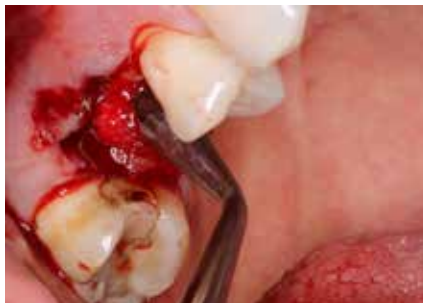

FIGURE 7: The OsteoGen Plug is firmly placed but not condensed like an amalgam.

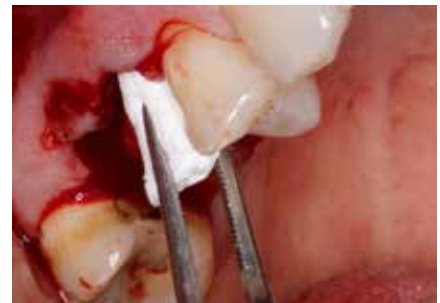

FIGURE 8: All three socket sites are filled with the OsteoGen material.

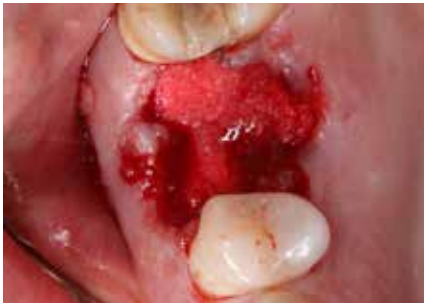

FIGURE 9: All three socket sites are filled with the OsteoGen material.

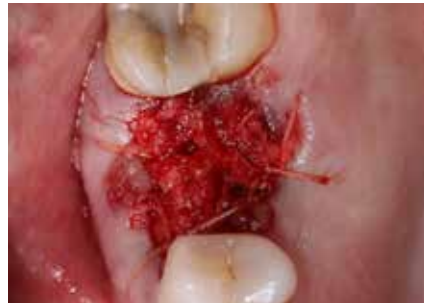

FIGURE 10: Vicryl sutures positioned over the graft to help maintain it in place.

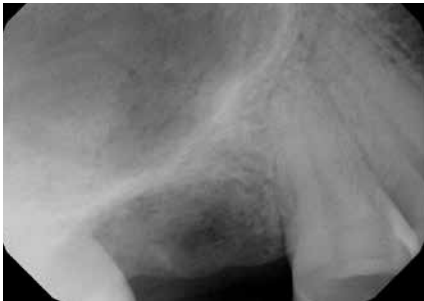

FIGURE 11: Immediate post operative radiograph illustrates a material that is somewhat radiopaque.

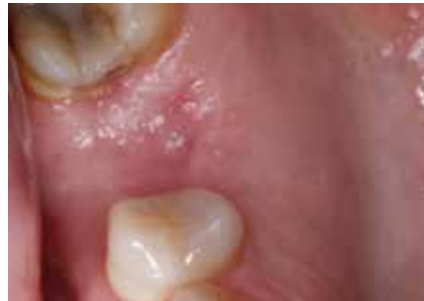

FIGURE 12: Four month post operative view illustrates epithelial growth over the defect.

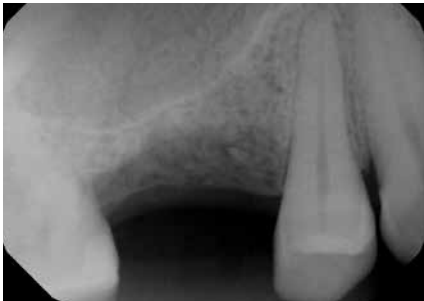

FIGURE 13: Radiograph illustrates bone formation in the socket site.

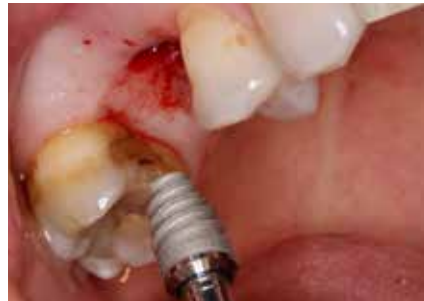

FIGURE 14: Following osteotomy protocol for implant placement, a Hahn dental implant is threaded into place and torqued to 40Ncm, creating initial stability.

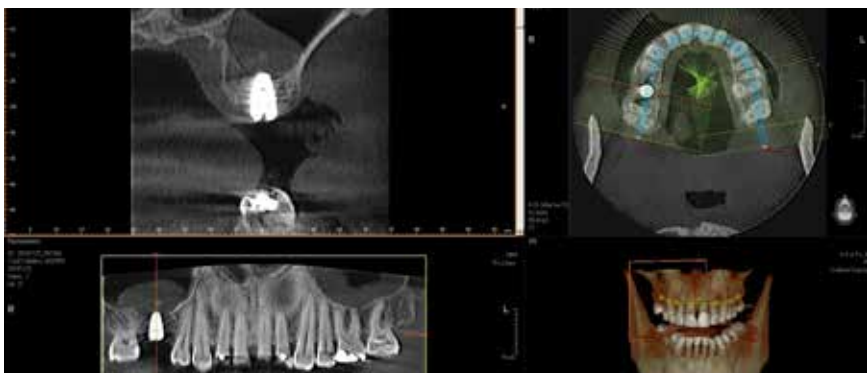


FIGURE 15: The post operative CBCT illustrates the implant properly positioned.

non-restorable tooth and take the roots and grind them to a particulate, which can be used as my graft material. The dentin particulate also has all the natural growth factors allowing osteogenesis to occur at a fairly rapid rate. (FIGURES 17-36)

The procedure to form autogenous graft particulate from extracted tooth is simple and precise. The Smart Dentin Grinder (GoldenDent, Detoit, MI) has a five step process that takes roughly fifteen minutes to complete. The first step is to remove any restorations or gross decay from the extracted teeth. Root canal treated teeth with gutta percha cannot be used. The coronal portion of the teeth may be removed to eliminate the enamel, which will not easily resorb.

The Smart Dentin Grinder system has a disposable chamber with blades that attach to the base of the table top motor. The roots are scrubbed and washed well and then air dried prior to placing in the blade chamber. The roots are ground to a particulate in about 20 seconds.

Following grinding, the a Dentin Cleanser made of 0.5ml of sodium hydroxide with 20% ethanol is used for ten minutes. This cleanser removes bacteria and any organic byproducts. A Dentin Wash is used next for three minutes; afterwards the excess cleanser is removed from the particulate. This is simply a buffered saline solution. That's it. The graft material is now ready to be used in the curetted socket site. The Smart Dentin Grinder creates 3-4 times the volume of the tooth in particulate and there is always adequate volume of graft material to use.

To prevent invagination of epithelial tissue into the graft, a long lasting resorbable membrane is passively placed over the socket and sutured down using a Vilet suture. (Implant

Direct, Thousand Oaks, CA) The Vilet is a polyglactin material that has high strength, resorbs to water and creates little tissue irritation.

Studies show that the autogenous graft particulate created here with the Smart Dentin Grinder has the same biological and chemical composition of natural bone. The material is osteoconductive and provides a scaffolding effect for osteoblasts that form new bone. Progenitor cells of the body, which convert to osteoblasts, are stimulated by the growth factors available. This provides for a more rapid turnover to natural bone, in preparation for the placement of a dental implant.

Normally I will allow approximately eight weeks for integration to progress prior to surgical placement of the implant, rather than the more conventional 4-5 months(4).

Patient acceptance is outstanding since we are using the patient's own bone, versus bone from another human or other source. To date the clinical results have been outstanding and the creation of grafting particulate from the patient's own dentin is an innovative and cost effective alternative to conventional techniques.

Minimally simple socket preservation techniques are an important adjunct following atraumatic extraction of teeth. This is especially true when considering dental implant replacement or even to maximize pontic design for bridgework. The loss of bone following extraction may be unpredictable and could result in a condition that impedes our ability to routinely place a dental implant.

The preceding clinical cases demonstrate two different ways to graft a challenging area. Both are safe and effective. Using the patient's own teeth to create a particulate has the advantage

FIGURE 16: A histologic sample taken at the time of implant placement illustrates bone turnover.

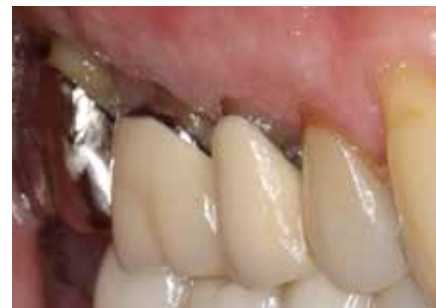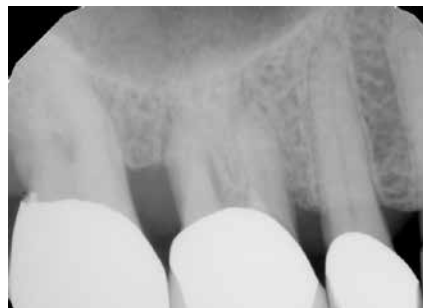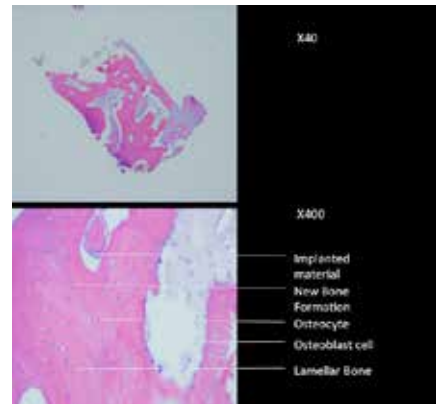


FIGURE 17 & 18: Pre operative radiograph of non restorable maxillary right first molar.

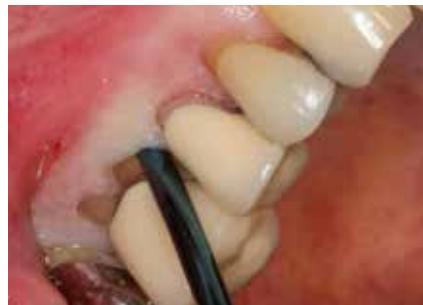

FIGURE 19: Physics Forceps Separators (GoldDent) are used to separate the root from the thin facial plate of bone.

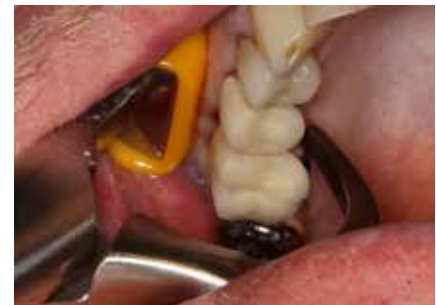

FIGURE 20: The Physics Forceps (GoldenDent) are used to atraumatically remove this 3 rooted molar tooth.

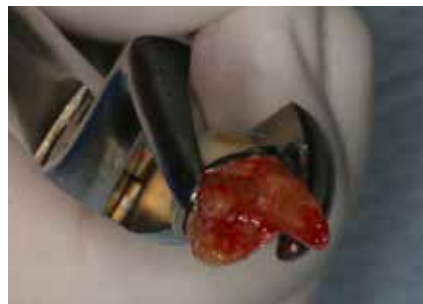

FIGURE 21: The roots of this tooth are divergent, yet easily removed using the Physics forceps.

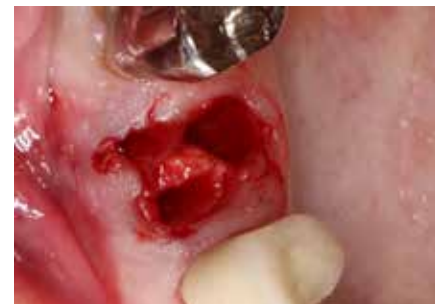

FIGURE 22: Following extraction the sockets are curetted to remove granulation tissue.

of a relatively faster turn around to bone formation. However, the graft material must be protected from invagination of epithelium with a membrane to make sure that the process is predictable. Using the OsteoGen Plug is a cost effective and highly predictable procedure that does not require a membrane. The bone formation is complete and provides a nice foundation for future dental implant placement.

These two solutions provide the clinician two options other than allograft materials and membranes that I find provide effective and predictable means of simple socket preservation.

*Dr. Timothy Kosinski is an Affiliated Adjunct Clinical Professor at the University of Detroit Mercy School of Dentistry and serves on the editorial review board of Reality, the information source for esthetic dentistry, the Michigan Dental Association Journal, and is the Associate Editor of the national AGD journals. He is a Diplomat of the American Board of Oral Implantology/ Implant Dentistry, the International Congress of Oral Implantologists and the American Society of Osseointegration. He is a Fellow of the American Academy of Implant Dentistry and received his Mastership in the Academy of General Dentistry. Dr. Kosinski has published over 180 articles on the surgical and prosthetic phases of implant dentistry and was a contributor to the textbooks, Principles and Practices of Implant Dentistry, and 2010's Dental Implantation and Technology. Dr. Kosinski can be reached at: 248-646-8651 or email drkosin@aol.com. www.smilecreator.net.*



FIGURE 23: The Smart Dentin Grinder (GoldenDent) is used to grind the patient's roots into an autogenous graft particulate. It is a self contained unit and consists of a motor and a disposable chamber, as well as a cleanser and saline wash vials.



FIGURE 24: The coronal portion of the tooth was sectioned off and placed into the Smart Dentin Grinder. Care was taken in removing any restorations, decayed structure and enamel. Root canal treated teeth should not be utilized for this procedure.



FIGURE 25

FIGURE 25, 26, 27: The unit automatically generates 250-1200 micron particulate autogenous graft, which is cleaned using the provided Dentin Cleanser followed by a Dentin Buffered Saline Wash.

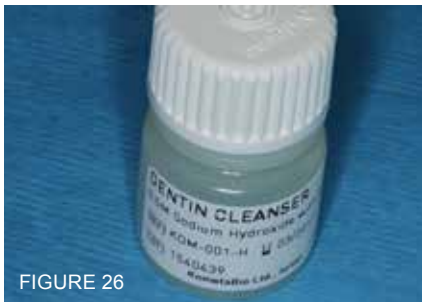


FIGURE 26



FIGURE 27

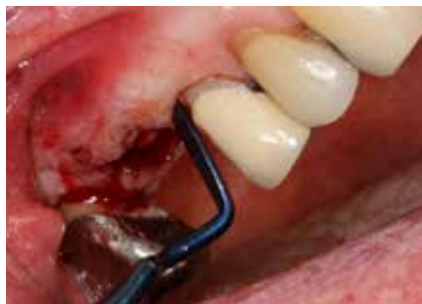

FIGURE 28: A long-lasting resorbable EpiGuide membrane (GoldenDent) is cut to cover the grafted site to prevent invagination of epithelial tissue.

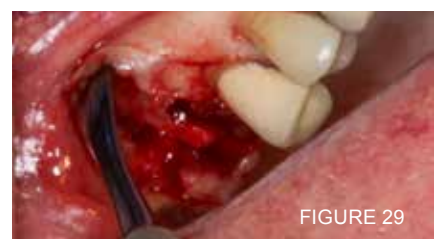

FIGURE 29

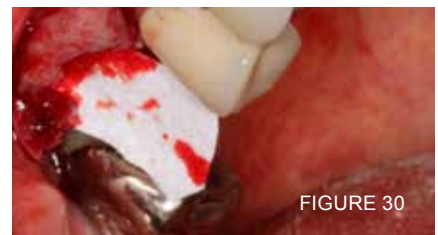

FIGURE 30

FIGURE 29, 30: An envelope flap is created using an Urban Knife (GoldenDent) to visualize the bony defects.



FIGURE 31: The membrane is passively positioned on the facial aspect of the envelope flap.

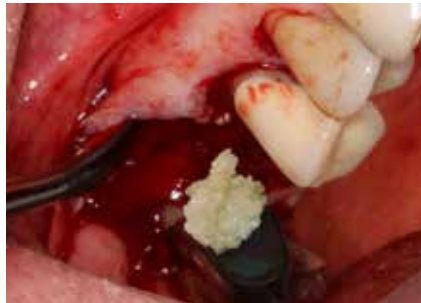

FIGURE 32, 33: The moist autogenous graft particulate is placed into the sockets and the membrane laid passively over the coronal portion of the ridge.

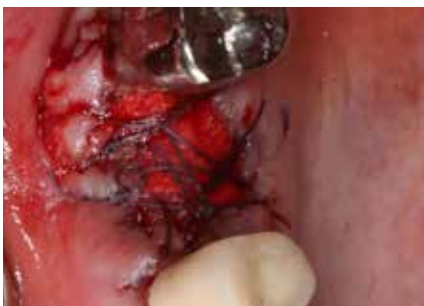
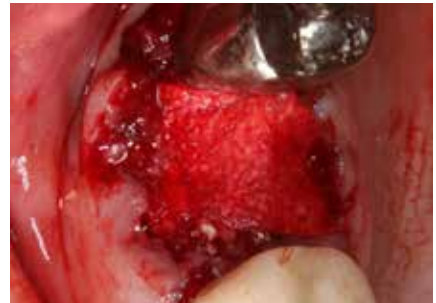
FIGURE 34: Violet sutures (Implant Direct, Thousand Oaks, CA) are used to keep the membrane in place.

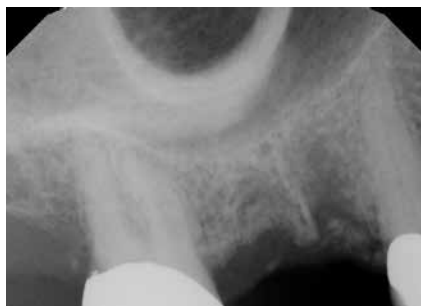

FIGURE 35: The immediate post operative radiograph illustrates the grafted material in place.

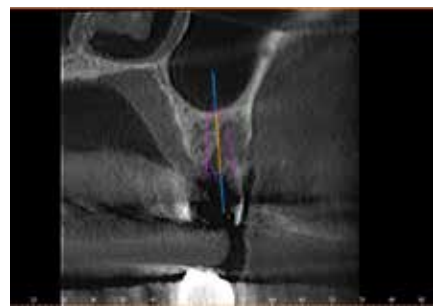


FIGURE 36: CBCT analysis allows virtual planning and placement of a future dental implant.

**REFERENCES:**

1. Horowitz, R., Rosen, D. "A Review on Alveolar Ridge Preservation Following Tooth Extraction." *J. Evid Based Dent Prac.* 2012.12.149-160.
2. Misch, C. "Maxillary Bone Grafting." *Dental Clin NA.* 2011.55.597-713
3. Misch, D., Dietsh, F. "Bone Grafting Materials in Implant Dentistry." 1993. 2(3)
4. Binderman, I., Hallel, G. et al. "A Novel Procedure to Process Extracted Teeth for Immediate Grafting of Autogenous Dentin." *J. Interdiscipl Med Dent Sc.* 2014. 2(6).
5. Valen, M. Ganz, SD. "A Synthetic Bioactive Resorbable Graft for Predictable Implant Reconstruction: Part 1." *J of Oral Impl.* 2002. 28(4). 167-177.
6. Artzi Z, Nemcovsky CE, Dayan D. Nonceramic hydroxyapatite bone derivative in sinus augmentation procedures: clinical and histomorphometric observations in 10 consecutive cases. *Int J Periodontics Restorative Dent.* 2003;23(4):381-389.
7. Ricci JL, Blumenthal NC, Spivak JM, et al. Evaluation of a low temperature calcium phosphate particulate implant material: physicochemical properties and in vivo bone response. *J Oral Maxillofac Surg.* 1992;50(9):969-978.
8. Corsair A. A clinical evaluation of resorbable hydroxylapatite for the repair of human intra-osseous defects. *J Oral Implantol.* 1990;16(2):125-128.
9. Epstein SR, Valen M. An alternative treatment for the periodontal infrabony defect: a synthetic bioactive resorbable composite graft. *Dent Today.* 2006;25(2):92-97.
10. Wagner JR. Clinical and histological case study using resorbable hydroxylapatite for the repair of osseous defects prior to endosseous implant surgery. *J Oral Implantol.* 1989;15:186-192.

**Did you know?**

*The contact information for every author can be found in the bio at the end of each article. Ask questions, learn more information about a particular product or service mentioned, or just use that resource to help build your network. Visit **MyEIDonline.com** for more great resources and to find back issues of *The Profitable Dentist* magazine.*

