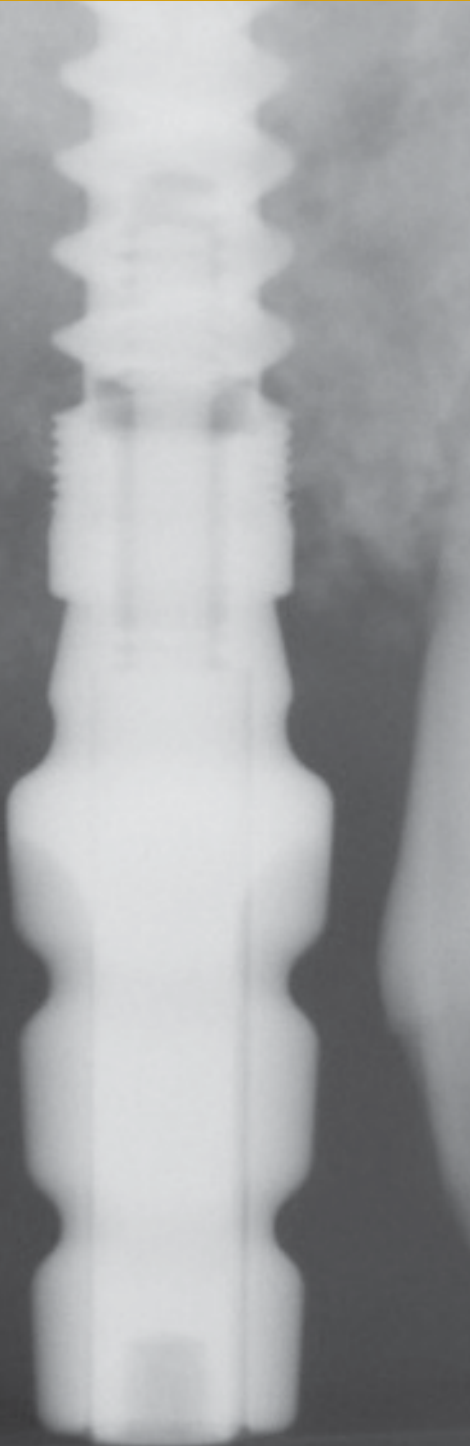


# Facial Wall Defect Grafting Techniques in Preparation for a Dental Implant

by Timothy Kosinski, DDS, MAGD



**D**ental implants certainly have become a popular method of restoring missing teeth. The procedures and protocol for our implant systems have provided outstanding prognoses. Patients often present with dental problems that warrant predictable and esthetic results. Expectations are high in society today. The general practitioner who achieves a high level of practical education on modern dental techniques is a step ahead. Being proficient at treatment planning complicated dental concerns is the first step in being able to effectively meet the esthetic goals of our patients.



The anterior maxilla presents some challenges. Losing a front tooth can be very traumatic to anyone. Imagine losing a front tooth. There are psychological issues that need to be addressed. Having a wide armamentarium of treatment options makes for a competent and effective dental practitioner. Dental implant therapy is just one of these procedures that make the dentist professionally and financially rewarded.

Surgical placement of dental implants has become somewhat routine with the advent of new designs and armamentarium and we are able to achieve remarkable prosthetic results when the implants are ideally positioned.

When presented with ideal edentulous ridges, surgically placing of a dental implant can be performed without complication. The use of dental CBCT analysis allows the practitioner to evaluate the condition of the edentulous space, review any vital anatomy and even allows for virtual placement of the implant prior to any surgical intervention on the patient.

However, often time conditions arise where placement of the implant is more challenging. Here we will discuss a circumstance in the esthetic zone of the maxilla where a root fracture resulted in significant bone loss. This situation requires the evaluation of the remaining bone and consideration for grafting of the defect with a bone building material.

The Hahn tapered implant system (Glidewell Direct, Irvine, CA) offers an efficient solution to demanding clinical situations including extraction sites. The system allows for precise control of angulation and positioning of the implant during surgical placement.

The threads are aggressive to maximize bone contact and initial stability. The surface of the implant is treated with a resorbable blast material to promote osseointegration. (1) The machined collar provides for soft tissue maintenance.

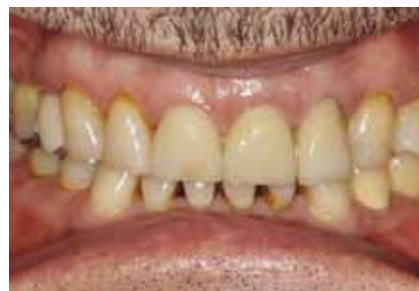The internal design of the implant is a conical hex. The length specific drills allow for easily visualization of the osteotomy preparation.

## A Case Study

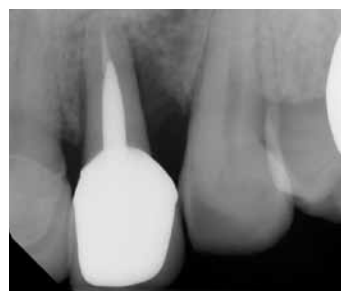Our patient is a 63 year old male who presented with a symptomatic and slightly mobile maxillary left lateral incisor. Oral hygiene needed to be addressed and improved. (figure 1) There were no medical contraindications noted. A radiograph indicated a horizontal fracture at the level of the post that had created a periodontal defect around the tooth. (figure 2,3) It was determined that the tooth was non restorable. Options presented to the patient included a removable appliance, a conventional three unit bridge or a single dental implant. As our patients have become very educated on the benefits of implant dentistry and the ability to treat the implant crown like a normal tooth, our patient elected on a single dental implant replacing the maxillary lateral incisor.

The maxillary anterior Physics Forcep (Golden Dental Solutions, Roseville, MI) was used to remove the fractured incisor. The “beak” of the instrument is placed onto the palatal aspect of the root approximately 3mm subgingival. (figure 4)The “bumper,” which serves simply as a fulcrum and is not a working part of the instrument, is placed high into the vestibule. Without squeezing the handles, the instrument is rotated with the wrist toward the corner of the nose. The tooth thus lifts down and outward out of the socket, maintaining the integrity of the root.

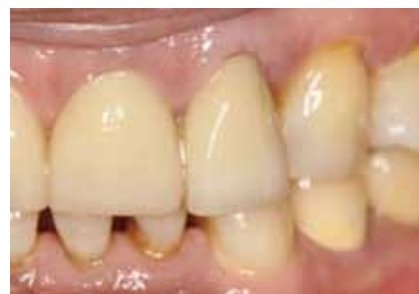The instrument is not intended to remove the tooth in total, rather to luxate it up to 3mm. A tooth delivery instrument illustrated in figures 5 and 6 lifts the tooth out of the socket. A radiograph is made to insure that the entire tooth root was removed (figure 7) Upon curetting of the socket it is



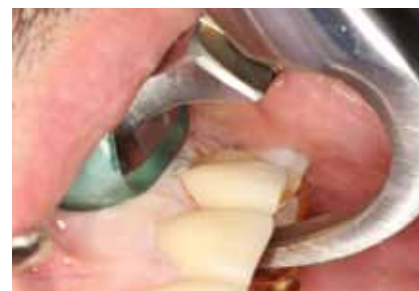**Figure 1:** Our patient presented with a periodontally failing maxillary left lateral incisor which will require extraction.



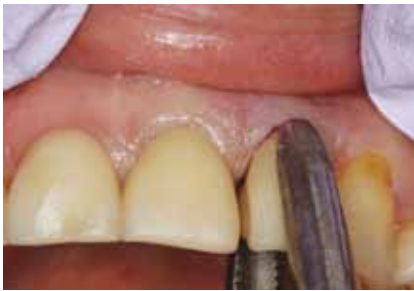**Figure 2:** The Periapical radiograph illustrates bone loss on the distal aspect most likely the result of a horizontal root fracture at the level of the post.



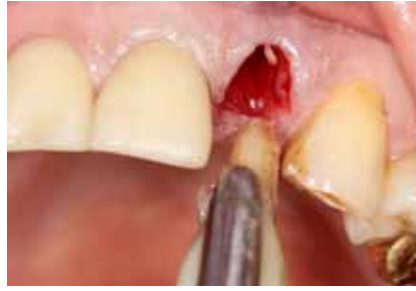**Figure 3:** Tissue changes are apparent on the facial aspect.



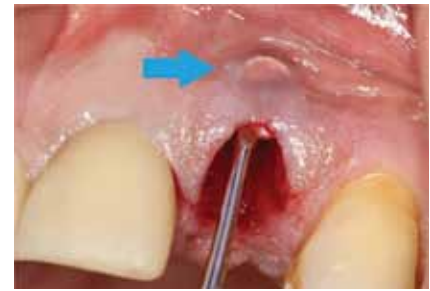**Figure 4:** An atraumatic extraction is performed using the Golden Dental Solutions Maxillary anterior Physics forcep. This forcep creates tension on the palatal aspect of the root and the rotation of the instrument lifts the tooth up and out of the socket site.



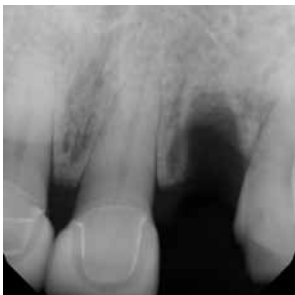**Figure 5:** A tooth delivery instrument is used to elevate the tooth out of the socket maintaining the soft tissue contours.



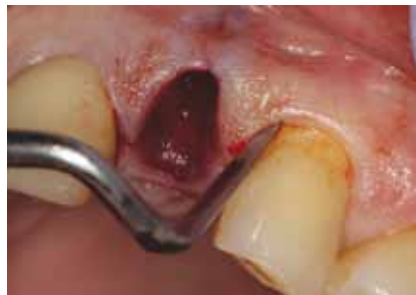**Figure 6:** The extraction is clean and precise without trauma to the soft tissue or adjacent teeth.



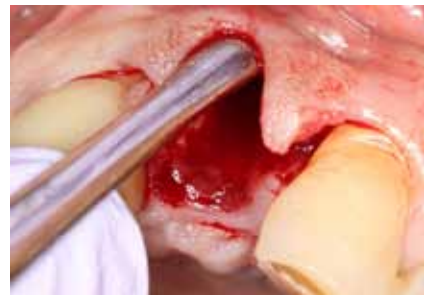**Figure 7:** Periapical radiograph of the extraction site.



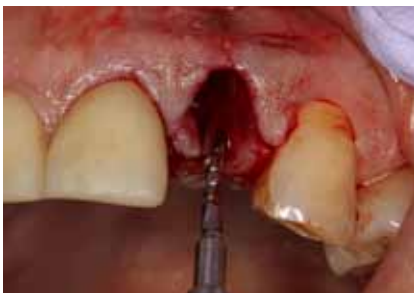**Figure 8:** Curetting of the socket reveals a significant facial defect as a result of the periodontal deterioration. This defect must be corrected to maximize final esthetics and emergence profile of the final implant retained crown.



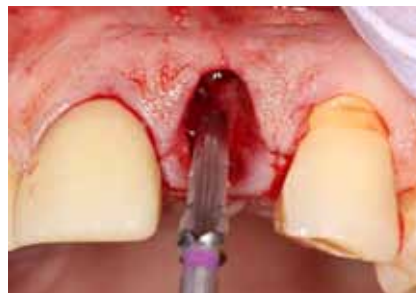**Figure 9:** An Orban knife is used to precisely incise the interdental papilla area so exposure of the facial defect will become apparent.



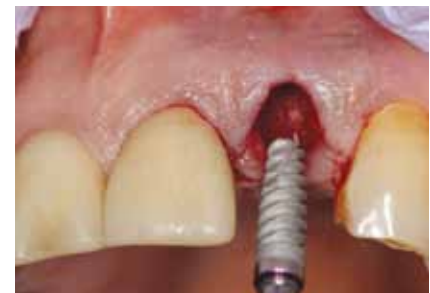**Figure 10:** A periosteal elevator is used to elevate the tissue past the facial defect. The palatal tissue is also reflected.



**Figure 11:** The Hahn dental implant system from Glidewell Lab uses a Pilot drill to make the initial osteotomy site. Note the positioning of the drill. We center mesial and distally between the adjacent teeth and position the initial penetration approximately 3mm palatal to the facial contours of the adjacent teeth. We do not go directly into the socket site, rather are palatally positioned using the palatal wall of the socket as a guide. Radiographs are made to insure proper angulation and depth for the implant.



**Figure 12:** Once proper angulation and depth are determined using the Pilot drill, the osteotomy is widened using the tapered osteotomy bur. Each bur is measured to a precise length, making crestal positioning easy to demonstrate.



**Figure 13:** Here a 3.5mm X 11.5mm Hahn dental implant will be torqued into the prepared osteotomy site. Note the aggressive threads of the implant which provide ideal initial stability in the compromised osteotomy socket.

clearly noted in figure 8 that the fracture resulted in loss facial bone.

If the practitioner is unsure of the nature of the defect, it is imperative that a conservative envelope flap be made using a Orban knife. (figure 9) This instrument allows ideal control when incising around the interdental papilla. This is referred to as a “papilla saving” flap. The envelope flap allows for visualization of the facial bone contours and dehiscence. (figure 10)

Prior to correcting the defect an osteotomy is created for a 3.5mm X 11.5mm Hahn Tapered implant. The 2mm Pilot Drill is used to idealize position facial-palatally and mesial-distally. (figure 11) The initial penetration is approximately 3mm palatal to the facial aspect of the adjacent teeth. Therefore the socket itself is not used as the ultimate guide.

A 3.5mm X 11.5 surgical drill then creates the final preparation. (figure 12) The Hahn Tapered implant (figure 13) was then torqued to proper position about 1mm subcrestal. (figure 14) The ideal position of the implant is around 3mm apical the cement-enamel junction of the adjacent teeth. The prominent design of the implant allows for precise, full seating of the implant which is torqued to 35Ncm.

A resorbable membrane (Epiguide, Curasan Corp.) was contoured to fit a minimum of 2mm apical to the facial defect and over the ridge to engage a minimum of 2mm of palatal bone. (figure 15) This will allow the membrane to lay flat and be maintained during the integration period. When done properly the membrane will not fall out. If a membrane is lost, the entire process becomes unpredictable. That is not to say that the graft will not work, we just are uncertain of the final result.

To fill out the facial aspect, demineralized cortico-cancellous allograft material (Gold-Oss, Golden Dental Solutions) was mixed with

sterile saline to create a paste (figure 17) The allograft has osteoconductive elements that promote new bone growth. Osteoclasts will invade the graft material and osteoblast will create new bone.

The graft material is packed firmly but the material is not crushed into place. (figure 18) The graft is made up of various size particles, which vary the eventual rate of resorption and bone replacement. The membrane is then laid over the crest of the ridge and is passively maintained (figure 19) This barrier prevents ingrowth of the epithelium and allows the osteogenic cells to create new bone. Vilet sutures (Riverpoint Medical, Portland, OR) was used to close the flap. This material has high tensile strength that is nice to have during the healing phase. (figure 20) The immediate post operative radiograph illustrates the position of the implant and the graft material surrounding. (figure 21)

After approximately 4 months of integration, the implant is exposed and an impression coping is seated into the body of the implant (figure 22). A conventional impression is made and sent to the laboratory for fabrication of an abutment and implant retained crown. To prevent epithelial covering of the implant, a 3mm tall healing abutment is torqued to 20Ncm. This allows the tissue to heal properly around the abutment. (figure 23)

Prior to placement of the final custom implant abutment, the healing abutment is removed illustrating a nice tissue cuff and healthy pink attached gingiva on the facial aspect. (figure 24) Note the position of the implant slightly palatal to the facial aspect of the adjacent teeth.

Figures 25 and 26 illustrate the seating of the custom prepared zirconia (Bruxzir) abutment. The margins are left at the gingival line angle, eliminating the possibility of cement affecting periodontal health which is sometimes seen with subgingival margins. The

final anterior esthetic Bruxzir crown is cemented with a transitional implant cement called Improv (Salvin Dental). (figure 27) It is my experience that tissue responds favorably to the zirconia material. Although complete tissue healing is not apparent and the dark interdental triangles are present, following a one week follow up one can visualize that because the extraction was atraumatic, the implant was immediately stabilized and physiologically positioned to promote emergence profile, and the facial defect was predictably repaired, the tissue response is excellent and the interdental papilla filled in nicely. (figure 28)

## Conclusion:

Proper planning for implant placement is imperative especially in the esthetic zone. Too often edentulous sites are not properly prepared resulting in a compromised prosthetic design.

Immediate placement of dental implants has become a popular method for obtaining the implant retained final crowns. Atraumatic extractions are an important aspect of this plan. Making the process atraumatic to the patient, especially when losing a front upper tooth is emotional, atraumatic to the dentist so that the tooth is easily removed without stress and atraumatic to the bone, thus maintaining interseptal bone which supports the interdental papilla is beneficial.

Losing facial bone can be a challenging predicament but with proper technique and materials repairing a facial wall can be accomplished. Short cuts cannot be taken, however, and the practitioner needs to understand the surgical incisions, graft materials used and the proper positioning of a high quality membrane. Initial stability of the dental implant is important and the body's physiologic reaction to bone replacement can be predictably obtained.

Implants today are prosthetically driven

and with the techniques described it is possible to maintain bone levels, bone width and optimize soft tissue contours to provide our patients with very acceptable outcomes.

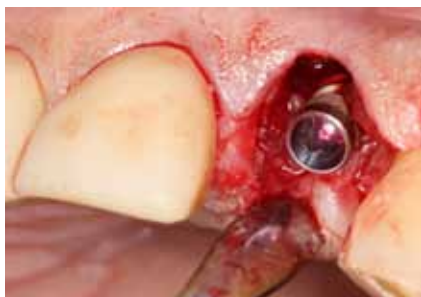*Dr. Timothy Kosinski is an Affiliated Adjunct Clinical Professor at the University of Detroit Mercy School of Dentistry. He is a Past-President of the Michigan Academy of General Dentistry. Dr. Kosinski received his DDS from the University of Detroit Mercy Dental School and his Mastership in*

*Biochemistry from Wayne State University School of Medicine. He is a Diplomat of the American Board of Oral Implantology/ Implant Dentistry, the International Congress of Oral Implantologists and the American Society of Osseointegration. He is a Fellow of the American Academy of Implant Dentistry and received his Mastership in the Academy of General Dentistry. Dr. Kosinski has received many honors including Fellowship in the American and International Colleges of Dentists and the Academy of Dentistry International. He is a member of OKU and*

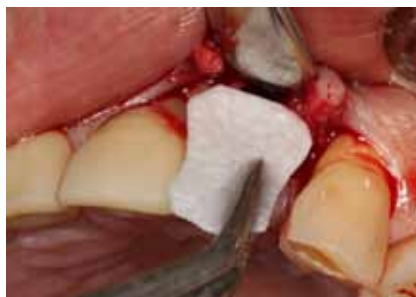*the Pierre Fauchard Academy. Dr. Kosinski was the University of Detroit Mercy School of Dentistry Alumni Association's "Alumnus of the Year," and in 2009 and 2014 received the Academy of General Dentistry's "Lifelong Learning and Service Recognition." Dr. Kosinski can be reached at 248-646-8651, drkosin@aol.com or www.smilecreator.net.*

**References:**

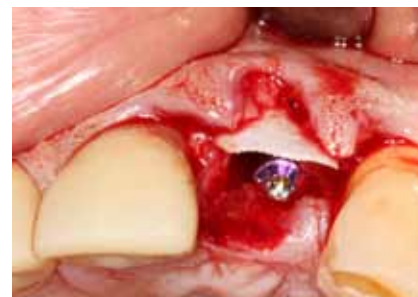1. Piattelli, M., Scarano, A et al. "Bone Response to Machined and Resorbable Blast Material in Titanium Implants." J. Oral Implantology. 2002; 28(1): 2-8.



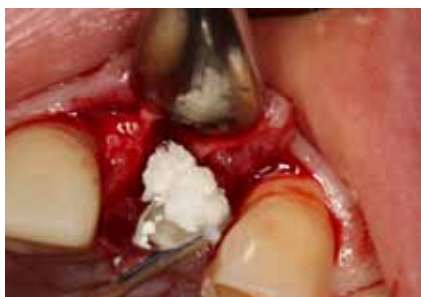**Figure 14:** The implant is positioned approximately 1mm sub crestal which allows for physiologic healing around the implant. Note, however, the facial wall is missing and will be augmented with allograft material and a membrane.



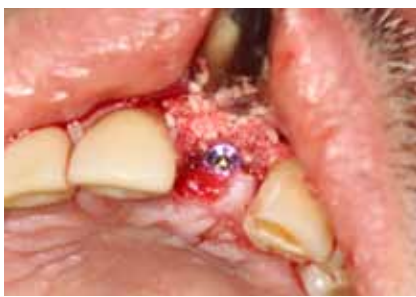**Figure 15:** A resorbable membrane (Epiguide) from Curasan Corp is cut to the proper size. Note that the membrane must extend a minimum of 2mm apical to the facial defect and at least 2mm on stable palatal bone. This will insure that the membrane remains in place during the integration period.



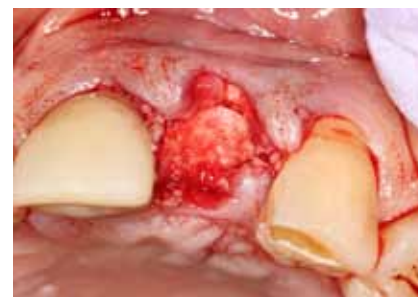**Figure 16:** I placed the membrane facially prior to any graft material being added. The membrane is secure without any force applied.



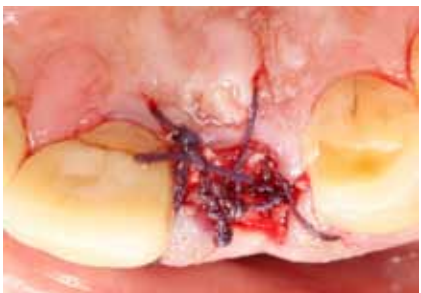**Figure 17:** Cortico-cancellous demineralized allograft material (Gold-Oss from Golden Dental Solutions), is wetted with sterile saline creating a gel. This material is then firmly packed against the membrane and into the facial defect.



**Figure 18:** The allograft material is not crushed into position, rather firmly packed. The facial defect has been filled in with the allograft material.

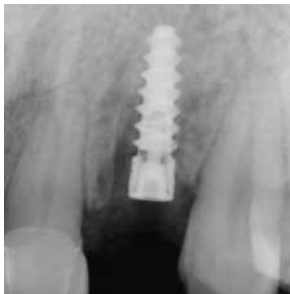

**Figure 19:** The membrane is then tucked over the site onto the palatal surface, tucked at least 2mm onto palatal bone. The membrane is passively positioned and will remain in place during the healing period.

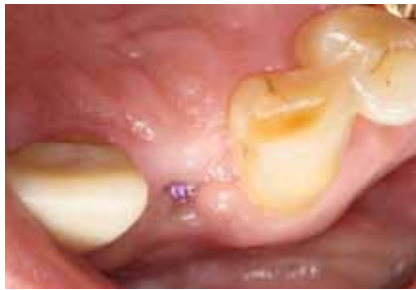

**Figure 20:** Vicryl sutures are placed over the surgical site to hold the tissue in place.

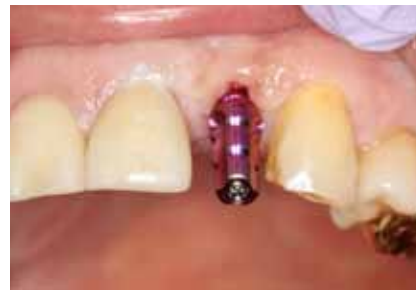



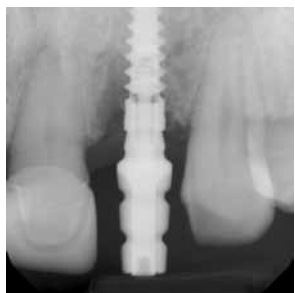**Figure 21:** Post operative periapical radiograph demonstrates the ideal position of the implant and the grafted material filling in the defect area. The implant is positioned approximately 3mm apical to the cement-enamel junction of the adjacent teeth. This again will allow for proper physiologic healing, maintenance of the interseptal bone and interdental papilla. This will allow for emergence profile and proper esthetics.



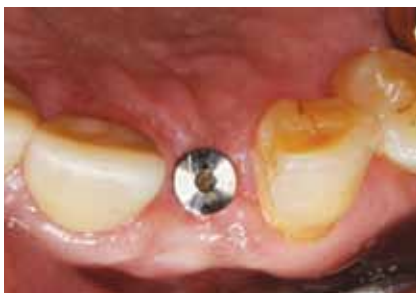**Figure 22:** An impression coping is placed into the implant after approximately 4 months of integration of the implant.



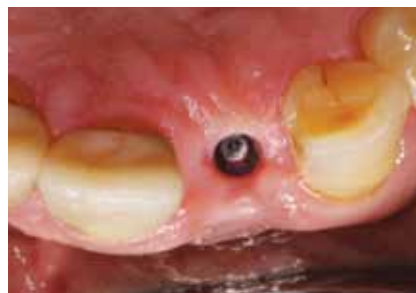**Figure 23:** After integration a 3mm tall healing abutment is torqued to place, note the healthy tissue and facial wall intact.



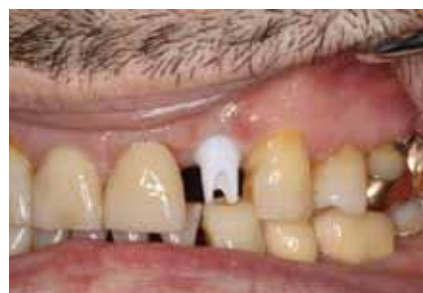**Figure 24:** The healing abutment provides for a healthy tissue cuff formation



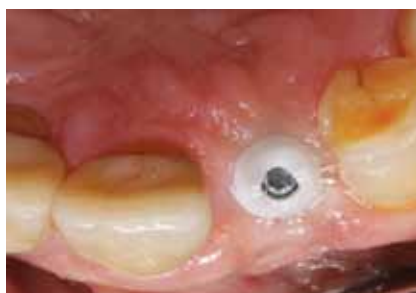**Figure 25:** A zirconia Bruxzir custom abutment is fabricated by Glidewell Lab. Note the margins of the preparation are at the gingival level. Blanching of the tissue is normal as the abutment contours are wider than the healing abutment.



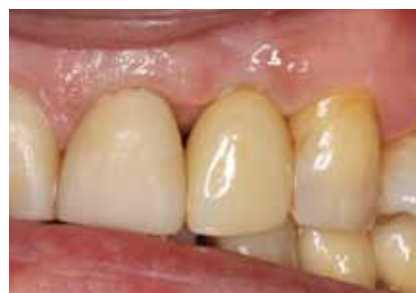**Figure 26:** Occlusal view of the margins of the custom abutment.



**Figure 27:** The final implant retained Bruxzir anterior esthetic crown immediately after seating.



**Figure 28:** One week follow up illustrates how the interdenal papilla was reformed due to physiologic positioning of the implant and maintenance of bone contours.



**Figure 29:** Need Caption