

**DIGITAL DIAGNOSIS AND TREATMENT PLANNING
FOR PLACEMENT AND RESTORATION OF SINGLE IMPLANTS IN THE POSTERIOR MAXILLA**

By Timothy Kosinski, DDS

Dental implants have undergone many positive advances in recent years. Our successes have dramatically increased, to the point where implant dentistry has become a constructive and simple alternative to conventional dental procedures. When a patient is missing one or more teeth, single dental implant-borne restorations can provide a functional esthetic result. Our newest materials can predictably match the structure, contour and lifelike qualities of natural dentition.

Partial dentures and bridges have been the treatment of choice in dentistry for generations. The results may indeed be acceptable, but the newest implant alternatives are better and less traumatic to the patient. We no longer have to grind down healthy tooth structure to replace single missing teeth, and patients no longer have to bear the restraints of a removable appliance. Today, dental implants are a viable and important part of tooth replacement in our practices.

The use of dental implants to support, retain and stabilize single crowns greatly improves the quality of life in patients who may have been deemed candidates for removable partial dentures. These partial appliances can be difficult to wear and make chewing difficult. Sore spots can make wearing them miserable, and they can move around the mouth while eating or speaking as well as cause social embarrassment. It is intuitive today that replacing missing teeth with a treatment that has proven to have an outstanding prognosis, is functionally strong and esthetically pleasing is a better option. Eating healthy foods is a part of life that should not be dismissed. Dental implants can help patients enjoy life again. The design of our modern dental implants, which follows basic engineering principles, has allowed the implant dentist to create beautiful, long-lasting solutions for patients' dental problems.

However, there are still concerns with any surgical procedure, especially in the sinus areas or in bone where nerves are located. These concerns have popularized the newest concepts in implant dentistry. We are now able to utilize our CAD/CAM computer software to virtually place our implants using CT scanning software to visualize the patient's entire oral anatomy in three dimensions, which takes all of a few minutes.¹ The reluctance to place implants in certain anatomic areas is eliminated with the virtual evaluation of anatomy and placement of the implants in question. We are now certain of ideal placement or have the ability to abort the case or consider additional procedures prior to ever touching the patient.

The information from a CT scan can be used by several scanning software programs. In this case we selected SimPlant. This system has an open architecture which allows us to virtually choose the desired implant and position it based on the vital anatomy.²⁻³ This technique is proving to be a cost-effective solution to assist the implant dentist in planning an esthetic final result and minimize any surgical challenges he or she may face. Patient acceptance is improved because concerns the individual may have can be addressed in a precise manner.⁴

CT technology is based on planning algorithms used clinically for many years. CT scans and 3-D planning software can greatly improve our predictability and safety. This technique can be used for single tooth edentulous spaces, like in this clinical case, partially edentulous spaces, fully edentulous maxillary and mandibular overdenture cases or fully edentulous maxillary and mandibular full arch permanent restorations. **The surgical cases are, therefore, driven by the final esthetic and functional result.** It is critical to make sure that the final tooth contours are established prior to any surgical intervention. Placing the dental implants in the jaw before understanding tooth position and the final result is a big mistake.

CT planning placement systems, like Simplant, provide a high level of comfort and safety for the patient by reducing surgical and restorative time. This is done by utilizing an accurate three-dimensional plan prior to implant placement. There are obvious advantages, including: easy visual understanding for clear case presentations to the patient, reduced surgical chair time, reduced restorative chair time in certain cases, reduced stress for the clinician and the patient, **the avoidance of surprises during surgery**, implants that are placed optimally for long-term implant and prosthetic success and, most importantly, an improved esthetic result.

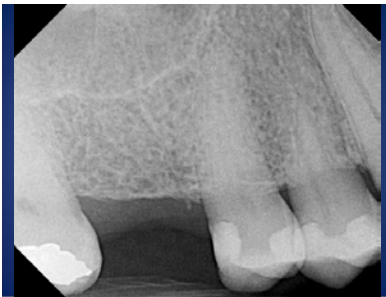Typically a scan appliance should be fabricated by the lab. This appliance shows the ideal prosthetic position of the teeth in the planning software. In a single implant case, such as this one, a CT scan of the patient can be used to diagnose and virtually place the implant of choice. The planning software allows you to drop in virtual teeth into the edentulous area.

The surgical placement of the dental implants can be done in a conventional manner using the information gathered in diagnosis using the CT image or a surgical guide can be created to help direct the implants in the ideal position. Based on the amount of attached gingiva these cases can often be completed through a flapless procedure.

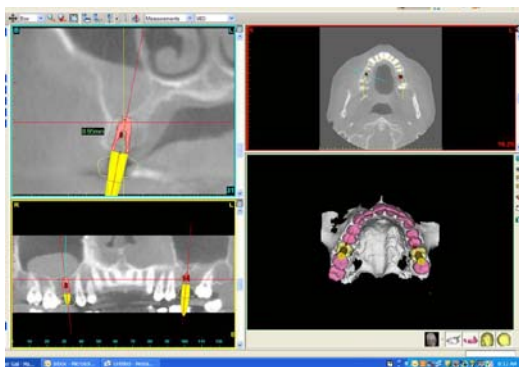
Our patient in the case that follows is a 44-year-old female with several dental problems. The right and left maxillary first molars had been extracted years earlier. The mandibular arch will be restored with grafting and implants in the future. Our main objective was to establish a correct occlusal plane relationship and improve the esthetics. Our choice of implants in this case was Sybron – Pro XRT dental implants (Sybron Dental Specialties, Orange, Calif.). The SybronPRO XRT implant design incorporates innovative micro threads, a mount-free delivery system and self-tapping threads.⁵⁻⁶ An internal octa or hex pattern allows for great stability of the platform switching abutments. Here, a 4.8 mm crestal width with a 4.1 mm body and 9 mm tall implant was used in the tooth #3 area. The determining factor in shape and size of the implant was based on the height and width of bone below the sinus. If less bone had been available then a sinus lift may have been necessary. The edentulous #14 area was an ideal place for a 4.1 mm X 9 mm internal hex implant. Two different types of implants were used in contra lateral positions to describe the surgical technique and final implant restorations of each design.

Figures:

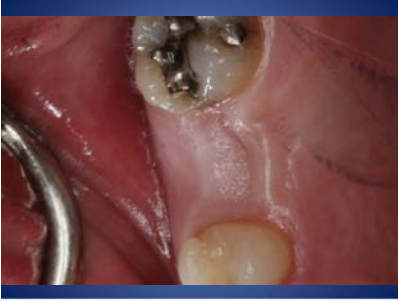1. Periapical of edentulous maxillary right first molar area. How much vertical and height of bone do we really have?



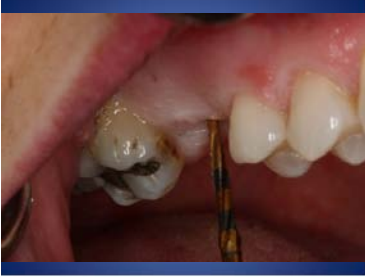2. CT digital plan illustrates panoramic cross-sectional and axial views as well as three-dimensional rendering of the patient's maxilla. Simple panoramic radiographs or periapicals do not give the three-dimensional image achieved with CT scanning. Note- The patient had a large polyp in the maxillary right sinus. The sinus membrane is slightly thickened on the left side.



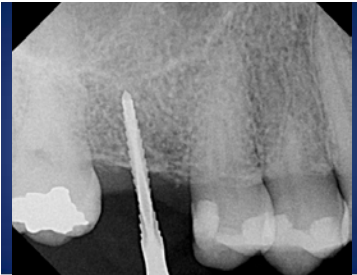3. Occlusal view of tooth # 3 area. It appears clinically that we have adequate width of bone, but the CT gives us an exact interpretation of the amount of bone we really have.



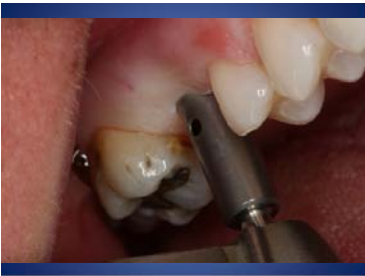4. The Sybron implant system is simple and precise. The first drill used to initially determine angulation is the Lindemann Guide. This is a very sharp drill with a point. It also allows for lateral positions, as it also cuts on its side.



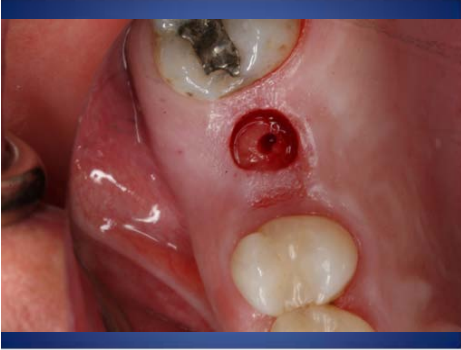5. A digital radiograph is taken to determine angulation of the primary drill.



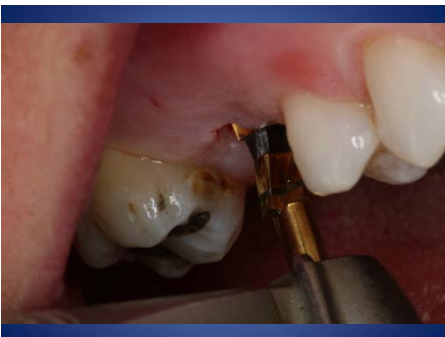6. A sharp tissue punch blade removes soft tissue at the surgical site and eliminates the need for a full thickness flap. Sutures will not be required after implant placement.



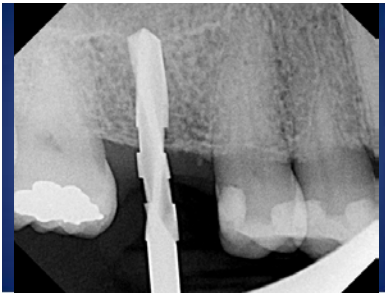
7. The soft tissue is removed with a curette.



8. The 2.2 mm diameter Twist Drill is used to establish depth followed by the 3.3 and 4.1mm Twist Drills. The black lines are clearly delineated: 7 mm, 9 mm, 11 mm, 13 mm and 15 mm. Note the gingiva was approximately 3 mm in height, so in determining a visual of how deep to place the implant, the 9 mm we want the implant to go into bone is added to the 3mm of soft tissue height. Therefore, the line markings on the Twist Drill are visualized to 12 mm.



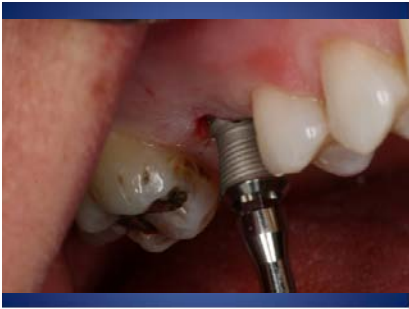9. Radiograph of 3.3 mm Twist Drill in site. Note the notches of the drill itself. The first break is at 7 mm, the second is 9 mm. This is intended to be our final depth, just at the floor of the sinus.



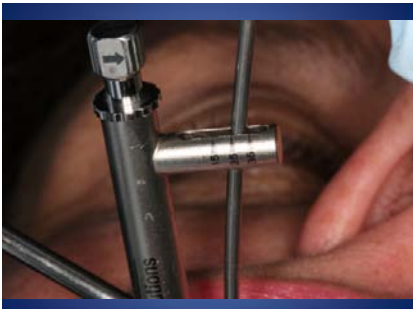
10. . The Sybron XRT-PRO Octa implant is picked up on the implant driver.



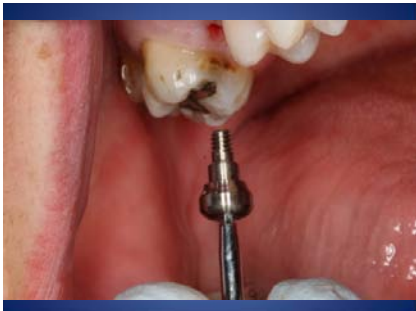11. The motor is turned down to record 25 Ncm of torque. The implant is driven into the osteotomy site and stops when 25 Ncm of torque is achieved.



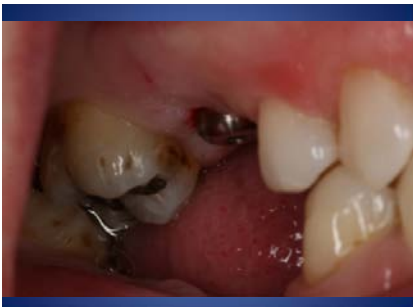12. Final seating and the tightness of the implant in bone is accomplished with the torque wrench. The wrench is marked at 15, 25 and 35 Ncm. We easily achieved 25 Ncm of torque on this implant in the maxillary right first molar area.



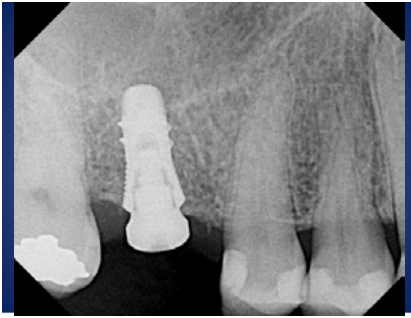13. Either a cover screw or a taller healing abutment can be safely placed into the implant to allow for tissue healing.



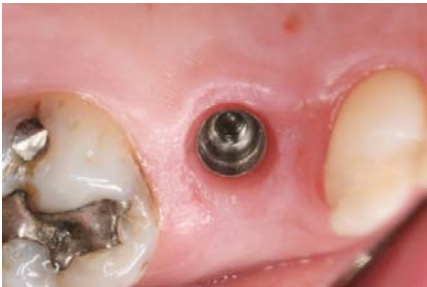14. The healing abutment is tightened to 15 Ncm, which will prevent any loosening during the healing phase. Note there is no bleeding; no sutures were required. This is a very non-invasive therapy.



15. A radiograph of Sybron Octa implant shows the position immediately after surgical placement. Note the platform-switching design of the healing abutment.



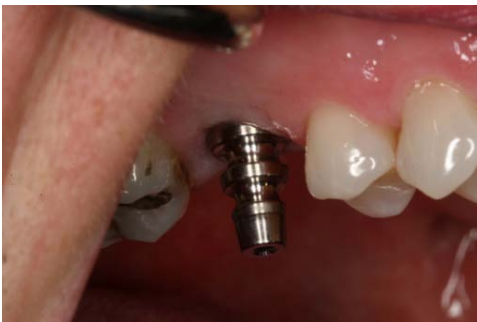16. Tissue healed around the healing abutment after 4 months of integration. The patient had no symptoms and only took a Tylenol for discomfort the day of surgery. The healing abutment is removed from the implant. Note healthy gingival cuff created by the healing abutment.



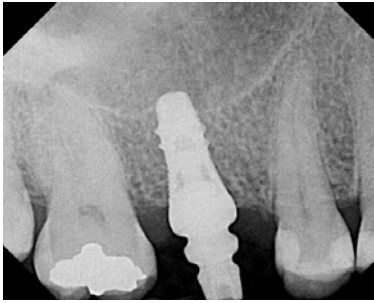17. A direct impression is planned. The impression system is a two-piece system with an octagon base that engages the internal design of the Sybron implant and a screw that threads it into position.



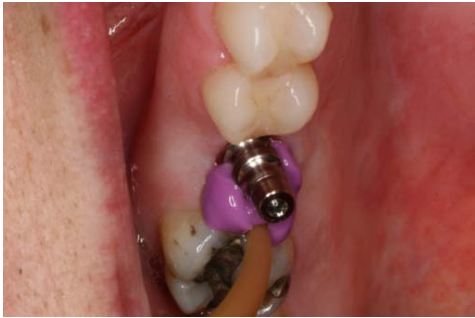18. A hex driver is used to place the impression coping.



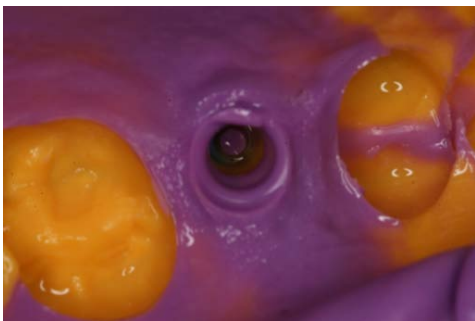19. A radiograph is taken to ensure a complete seat of the impression coping. This is a mandatory protocol procedure to ensure that the impression coping engages the implant completely.



20. A polysiloxane impression is made with light and heavy body material.



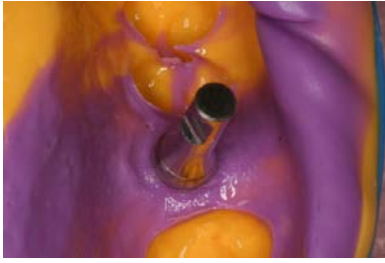21. Note the clean contours of the impression. The impression coping must be retained properly in the impression to ensure a proper abutment and crown fabrication.



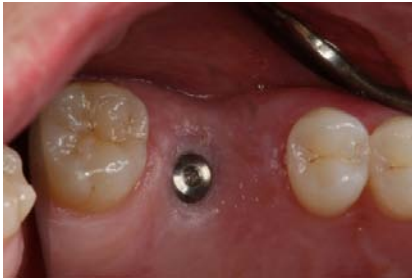22. The impression coping is removed from the implant and mounted onto a laboratory implant analogue



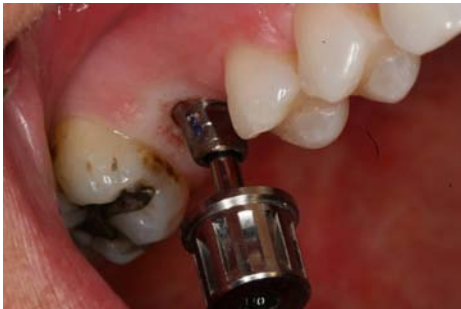23. The head of the impression coping is reseated into the impression, a shade taken and the case sent to the lab.



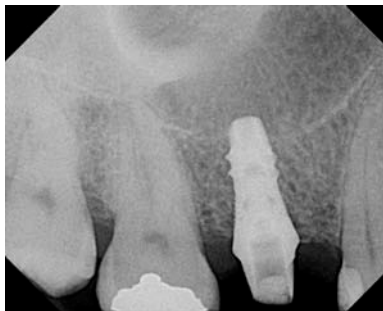24. The healing abutment is replaced in the mouth while the dental laboratory makes a master cast using the implant analogue to fabricate the proper abutment and crown.



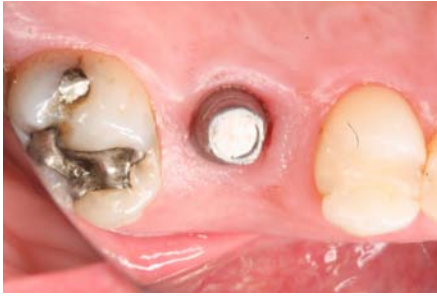25. The healing abutment is removed. The prepared abutment is seated and the abutment screw tightened to 25 Ncm



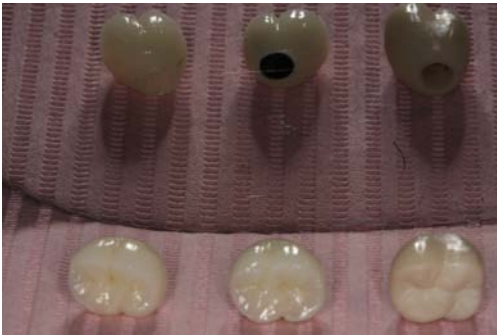26. A radiograph is taken to ensure a complete seating of the abutment into the body of the implant.



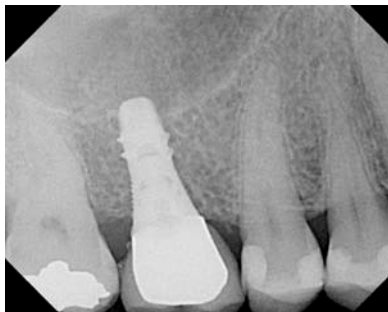27. A piece of cotton or silicone is placed into the screw hole after tightening the abutment screw to the recommended torque. A little Cavit is used to cover the screw hole prior to crown cementation.



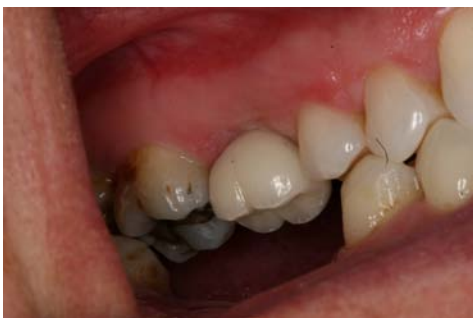28. Three different designs and types of crowns can be fabricated by the dental laboratory including esthetic and durable Prismatic CZ zirconia crowns (zirconia coping with porcelain veneer), conventional porcelain fused to metal or Bruxzir solid-zirconia. It was determined that the zirconia crown was the most esthetic and would be durable.



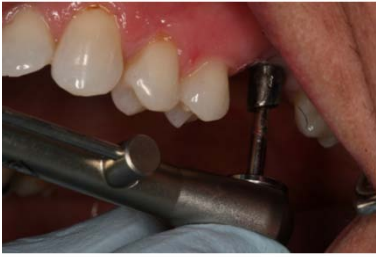29. The zirconia crown is cemented into place.



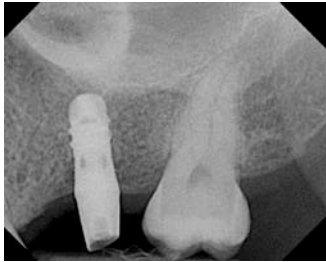30. Final radiograph of implant-retained maxillary first molar cemented into place.



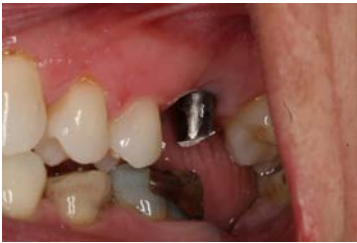31. Delivery of the final prosthesis for #14- The healing abutment is removed, the hex abutment is seated and the abutment screw tightened to 25 Ncm.



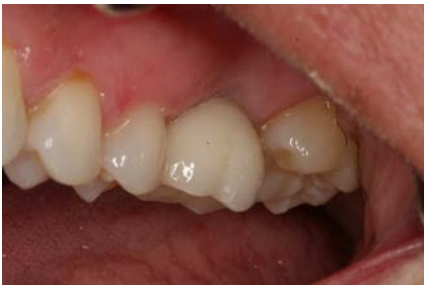32. A radiograph is taken to ensure complete seating.



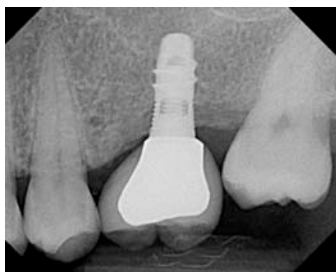33. The abutment screw opening is covered with silicone or cotton and Cavit prior to crown cementation.



34. The Prismatic CZ crown is cemented onto the abutment.



35. PA of the final restoration.



Conclusion

Implants provide an excellent option for restoring missing single teeth. The use of CT scans and planning software provide an invaluable treatment planning tool. This case highlights the technique to restore missing posterior maxillary teeth utilizing a minimally-invasive surgical procedure leading to an esthetic, functional prosthetic result.

References

1. Kosinski T. *Optimizing implant placement and aesthetics: technology to the rescue! Dentistry Today* Aug 2009.
2. Ganz S. *Computer-aided Design/Computer-aided Manufacturing Applications Using CT and Cone Beam CT Scanning Technology. Dent Clin North Am.* 2008 Oct;777-808.
3. Rosenfeld A, Mandelaris G. *Prosthetically directed implant placement using computer software to ensure precise placement and predictable prosthetic outcomes. Int J Periodontics Restorative Dent.* 2006 Jun; 26(3):215-21.
4. Amet E, Ganz S. *Implant treatment planning using a patient acceptance prosthesis, radiographic record base, and surgical template. Part 1: Presurgical Phase. Implant Dent* 1997;6: p.193-197.
5. Kharouf, Zeineb; oh, Hyeong Cheol, Saito, Hanae et al. *Dept. of Periodontology and Implant Dentistry, New York University. Surgical and Mechanical Techniques to Increase Stability of Dental Implants presented at the 23rd Annual Meeting of the Academy of Osseointegration in Boston, MA 2008.*
6. Gittleman N. *Immediate Loading of Sybron Pro XRT Implants in the Symphyseal Region. J. of Implant and Advanced Clinical Dentistry.* 2009 July-August; 1, (5): 45-49.